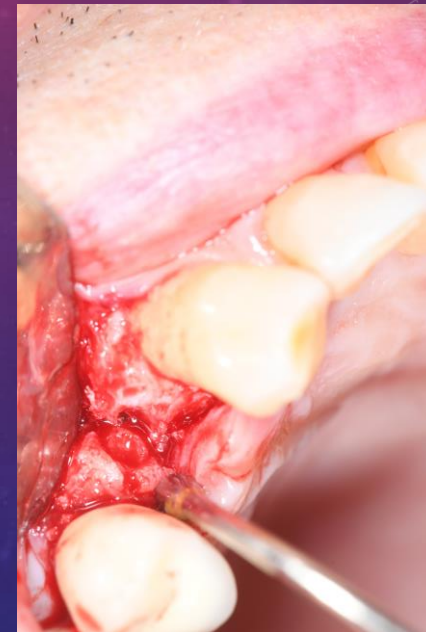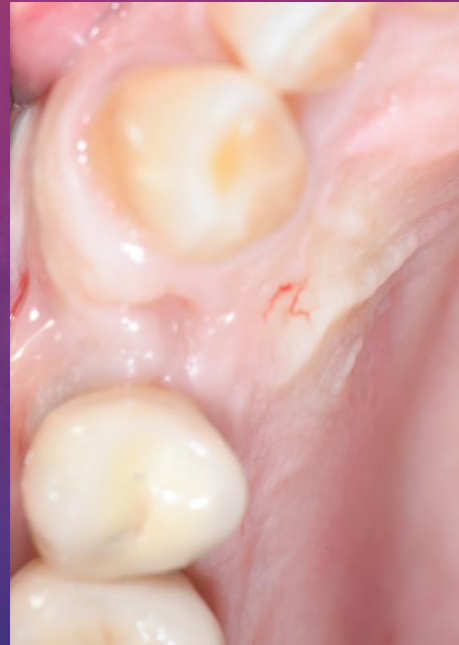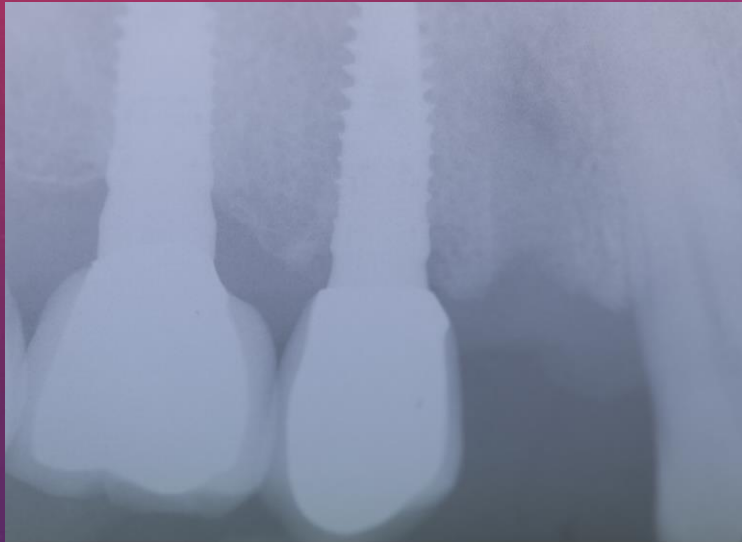
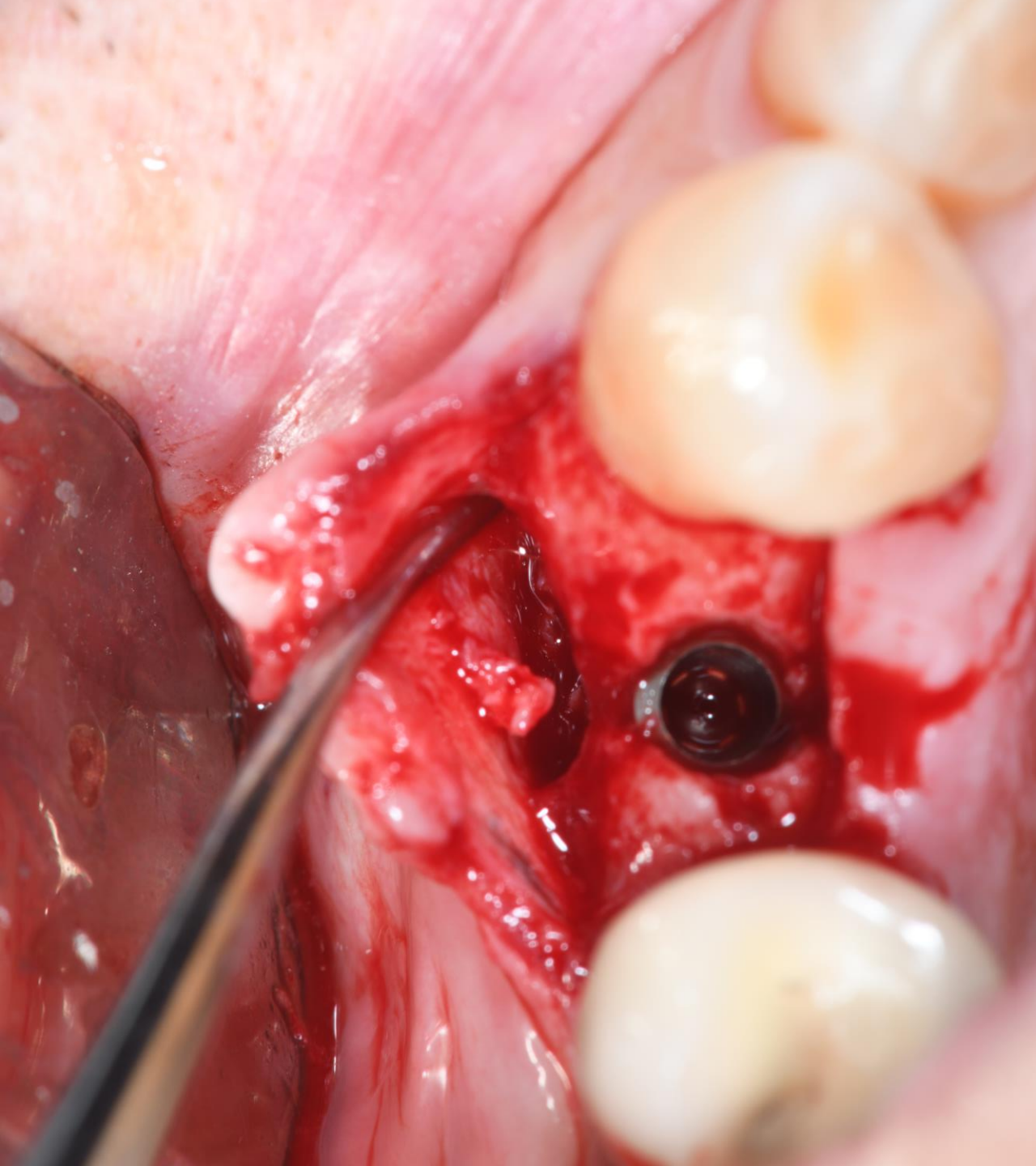
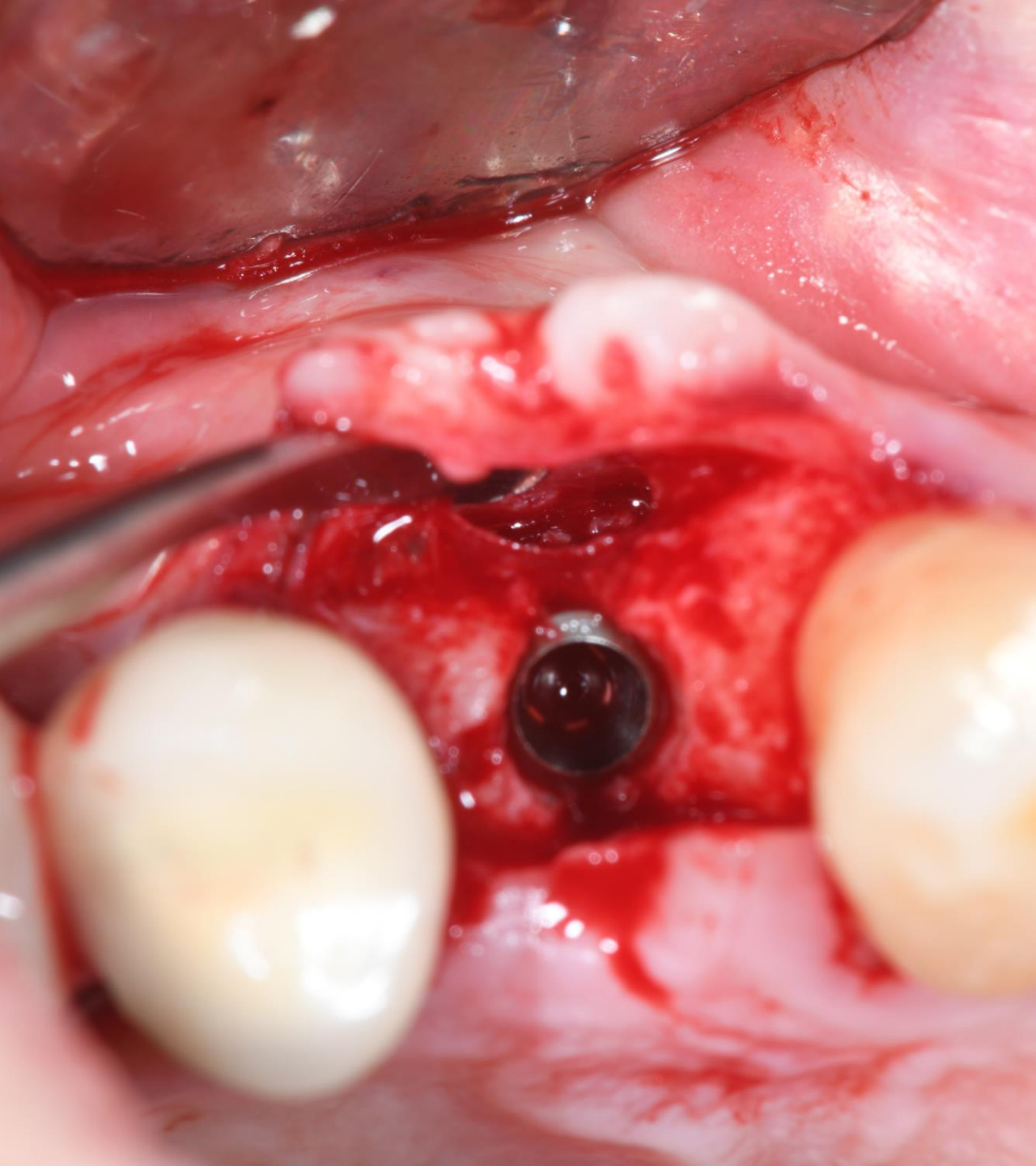


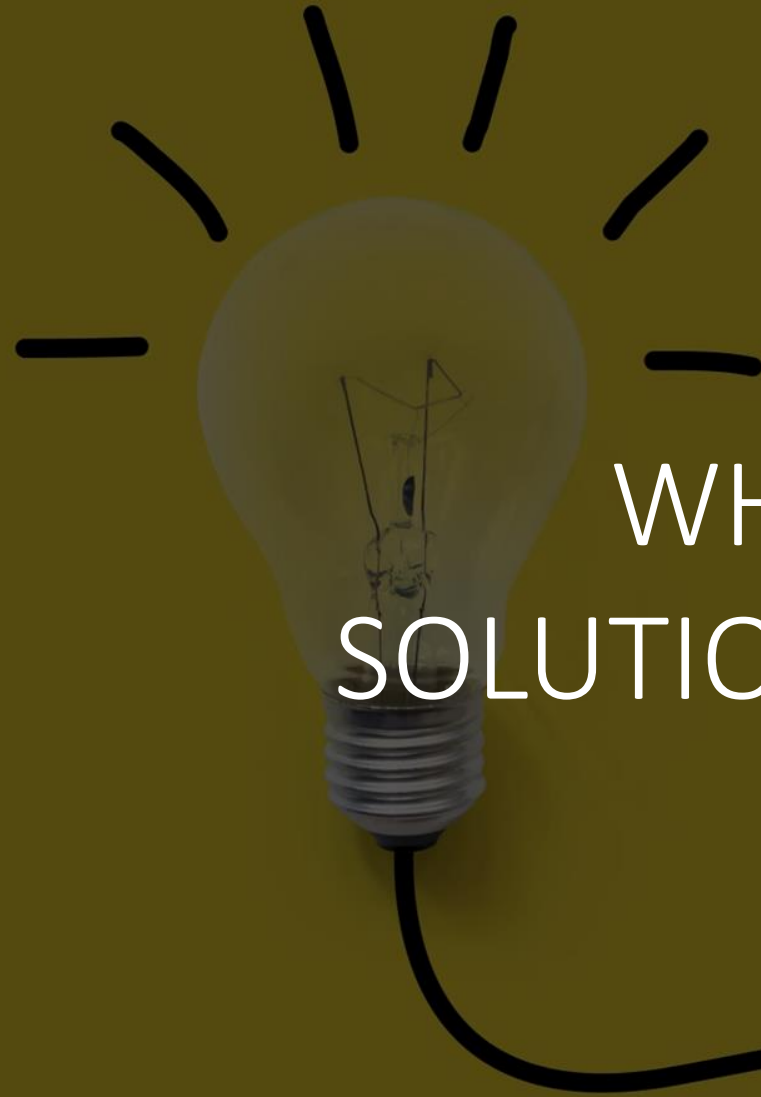Cases TRASARTI S

T

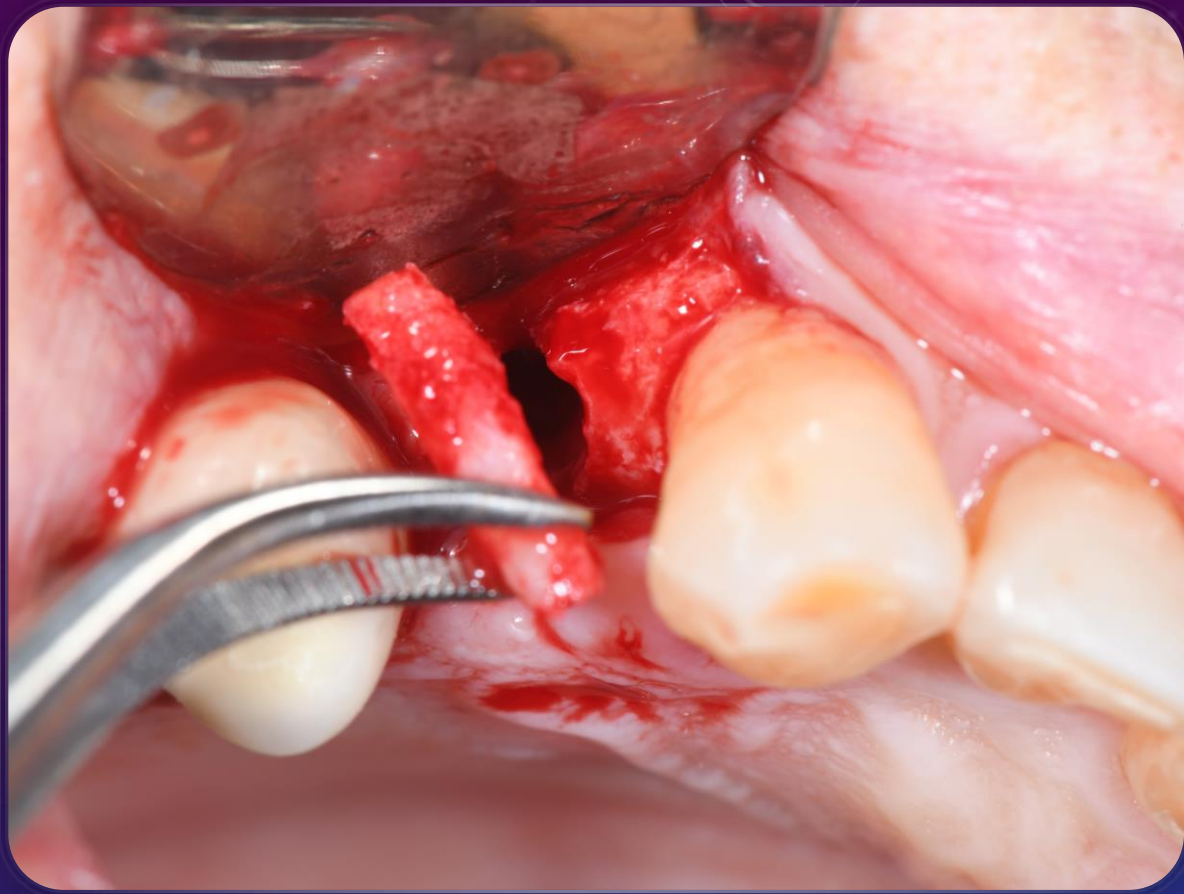
SITUATION AFTER TWO MONTHS OF EXTRACTION



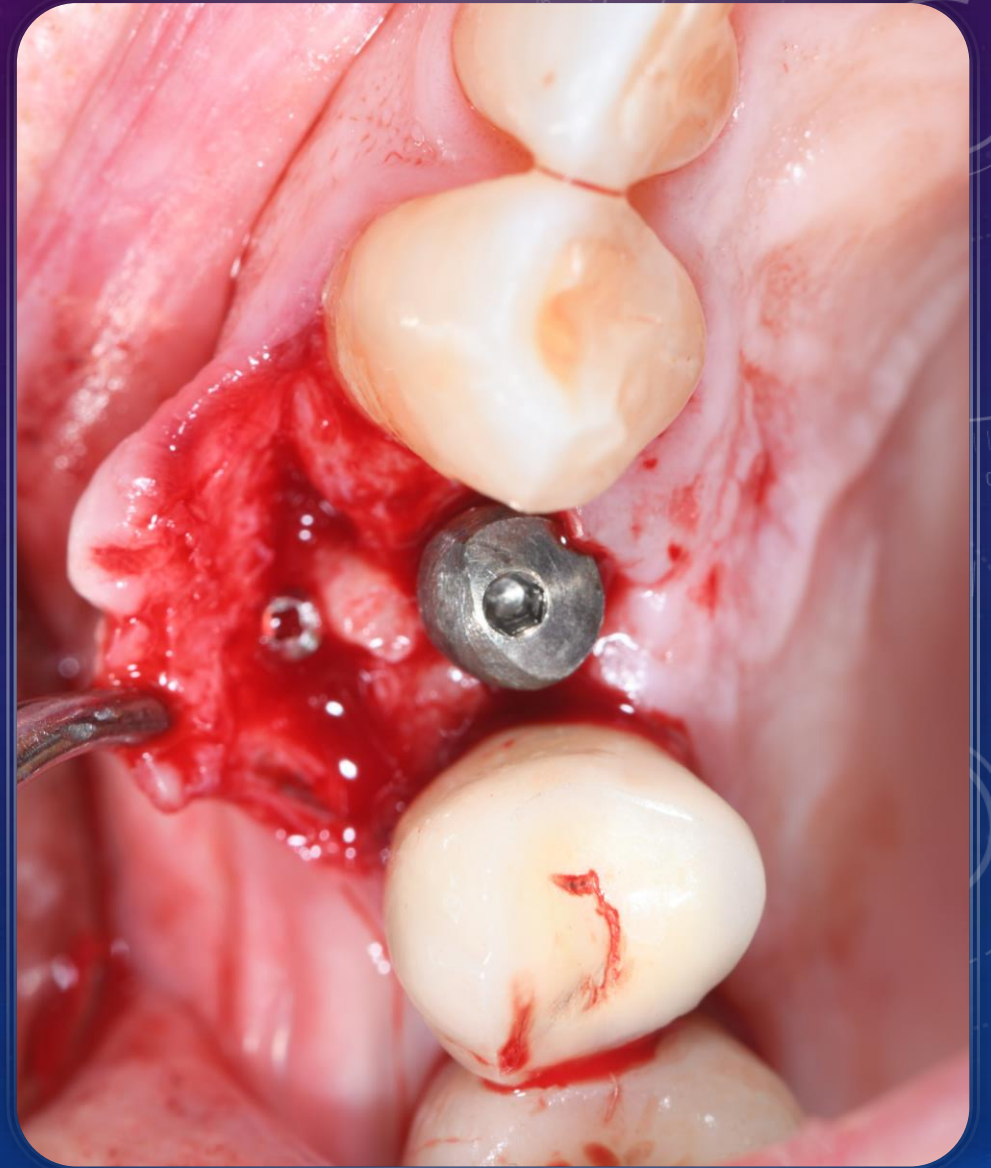




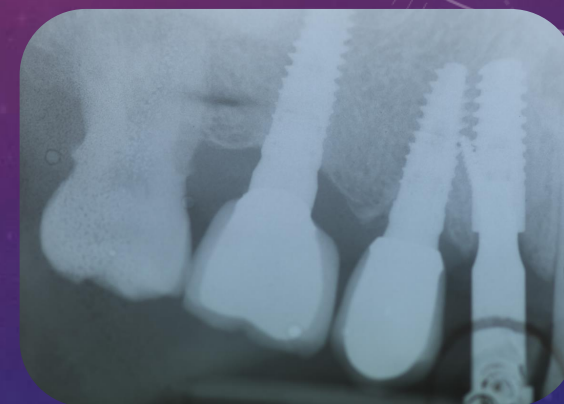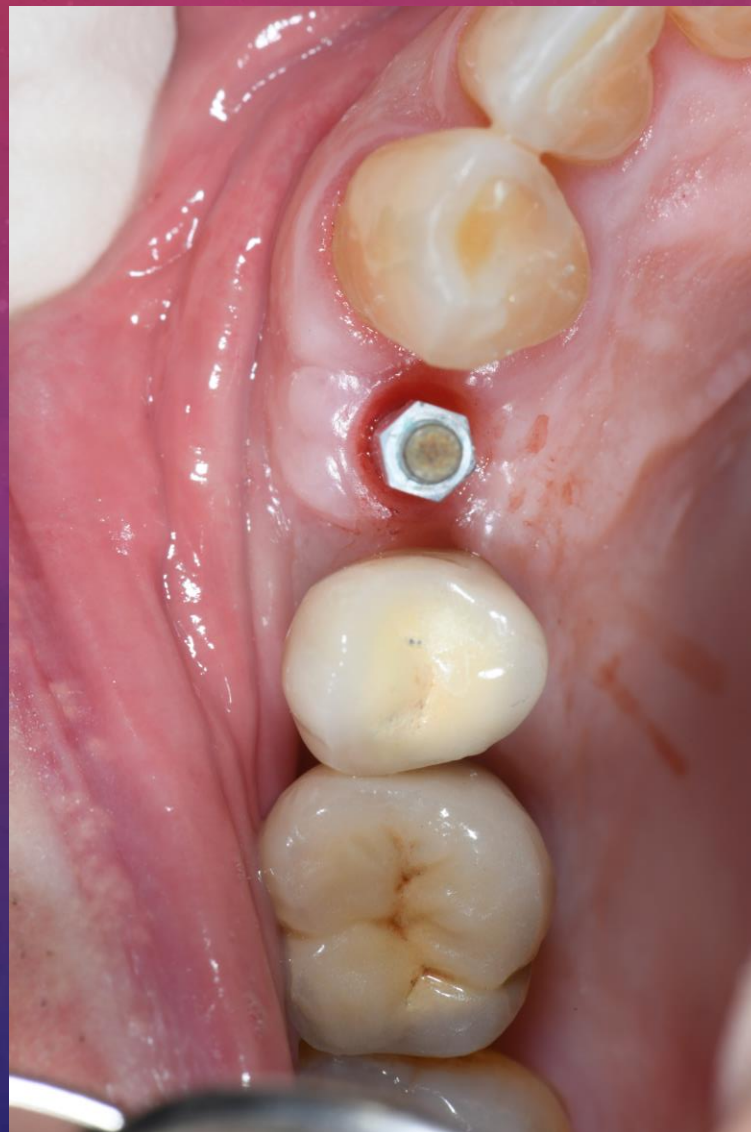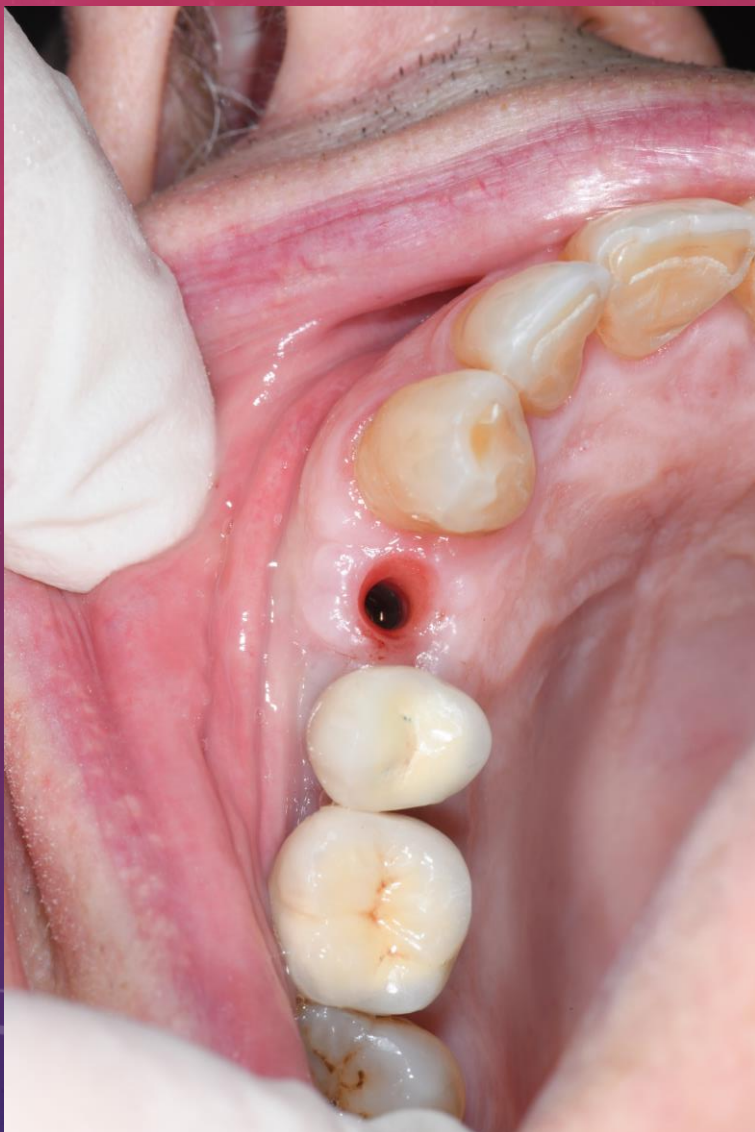WHAT
SOLUTION?



- Subcrestal implant after two months
- Healing screw and bone augmentation Torque 36
- Age: 79
- Drugs : Anticoagulants
- ISQ green

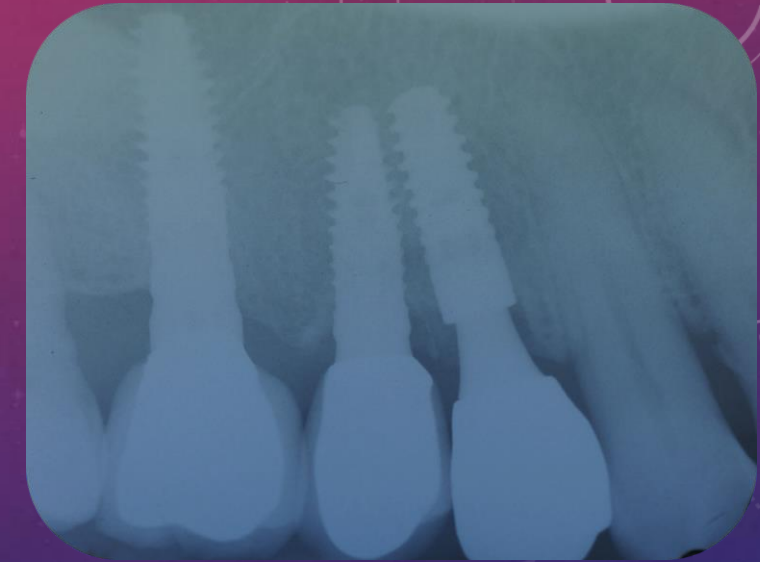
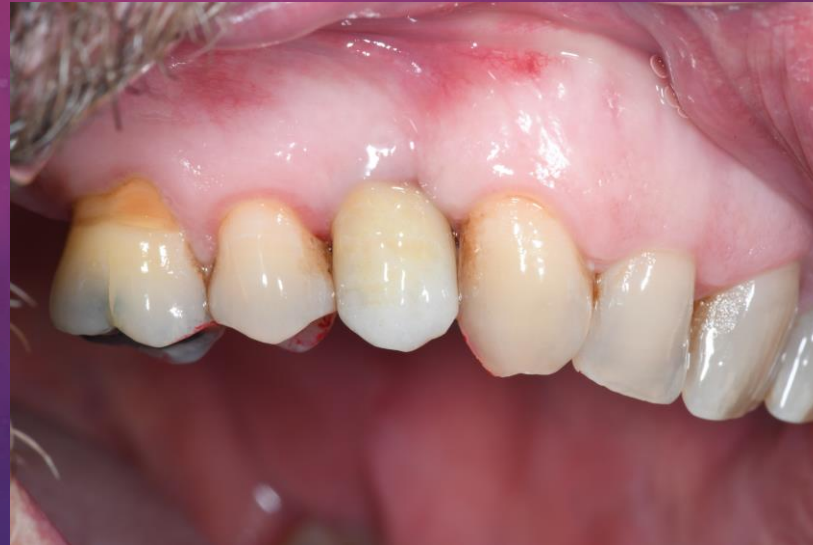
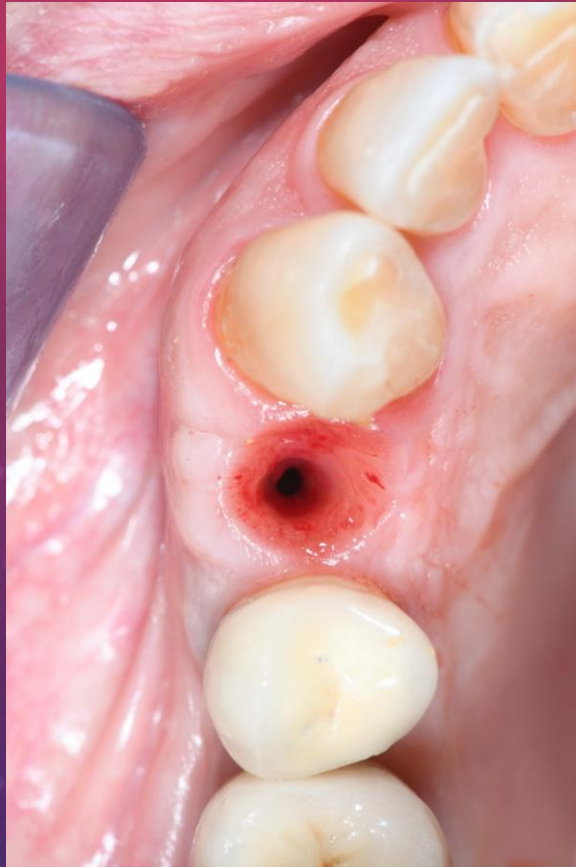
AFTER ONLY TWO MONTHS

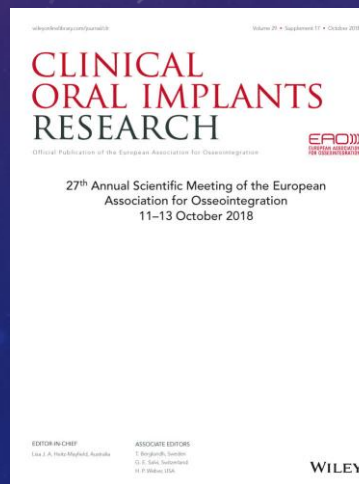

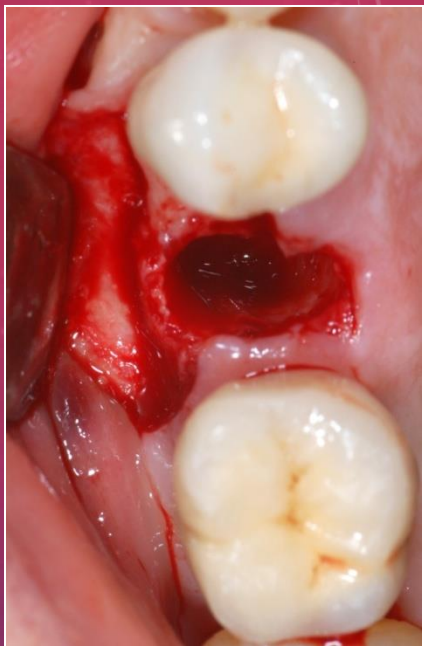
Importance of hard tissues

1 year from loading

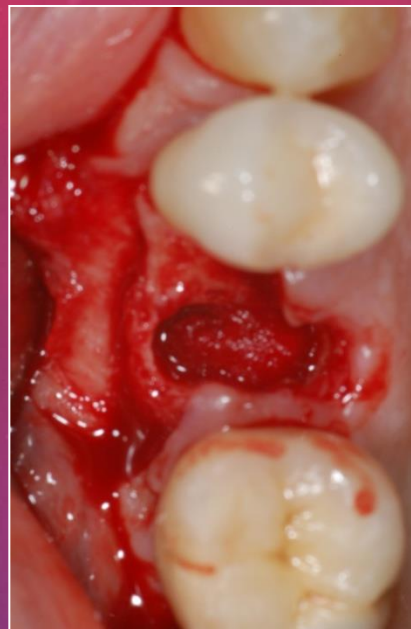

→ **Trasarti S et al**: The new bone core technique for small bone defects. **Clinical Oral Implants research** 2018;29(Suppl. 17)

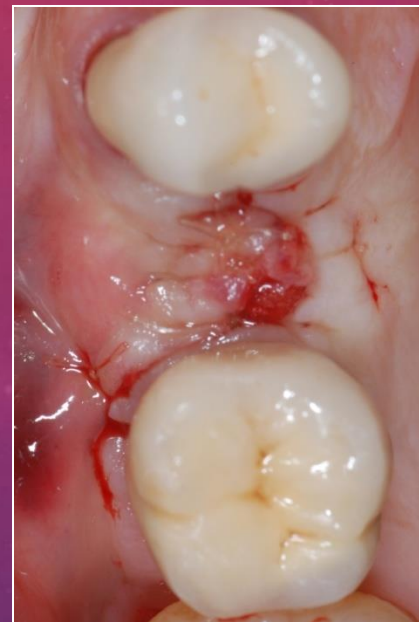



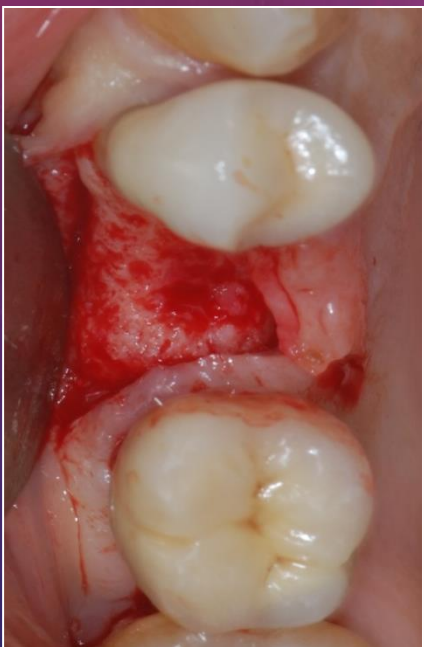
Ex 15



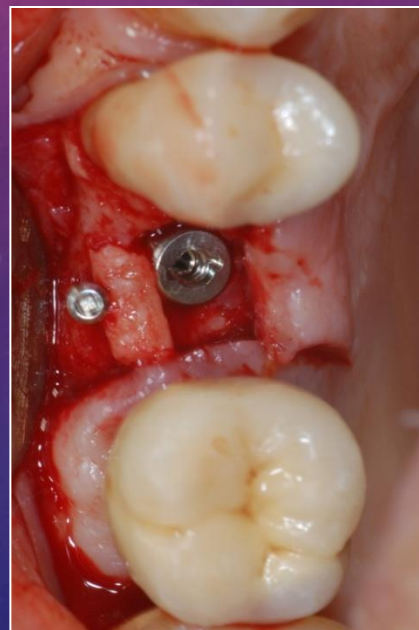
Collagen



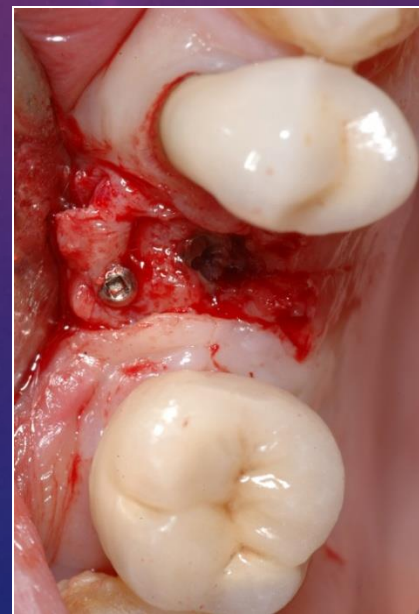Suture




After 3 months

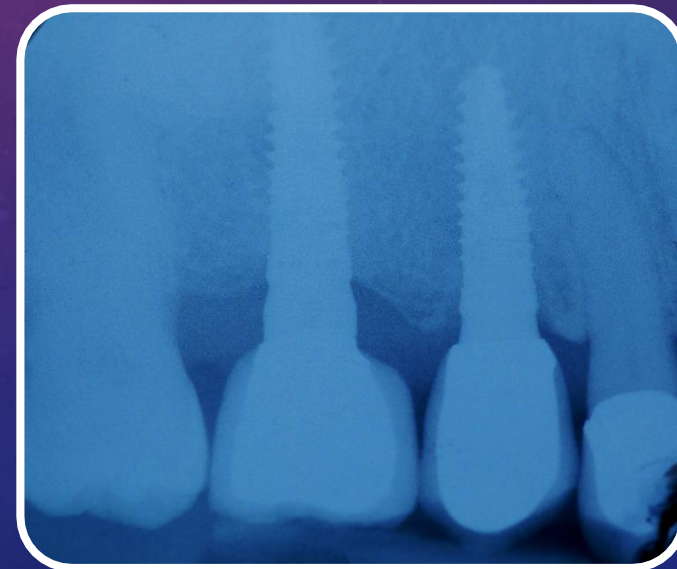
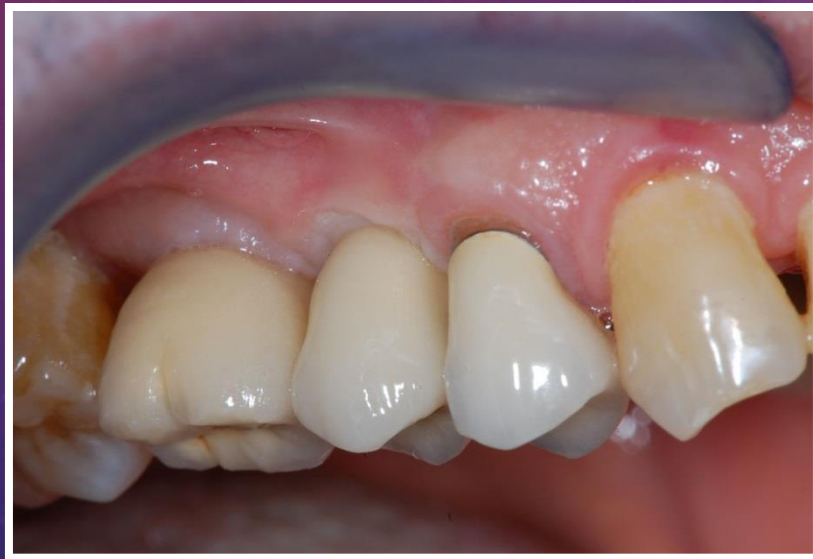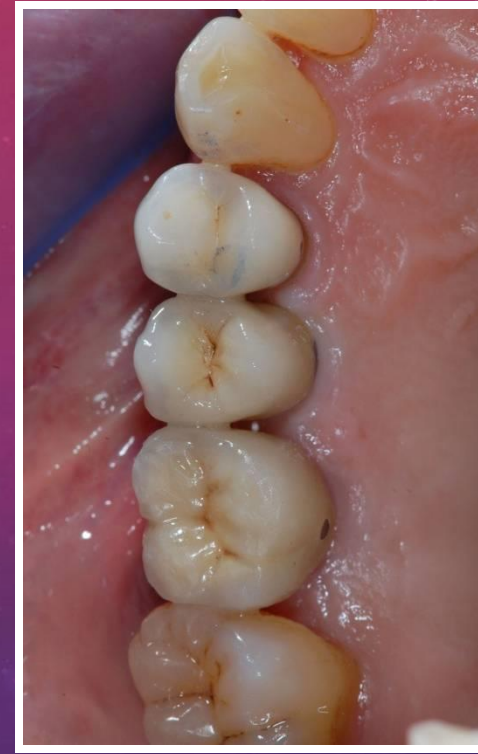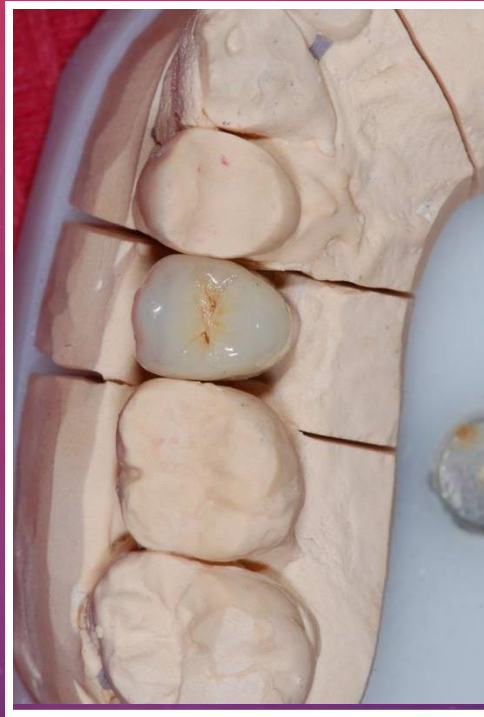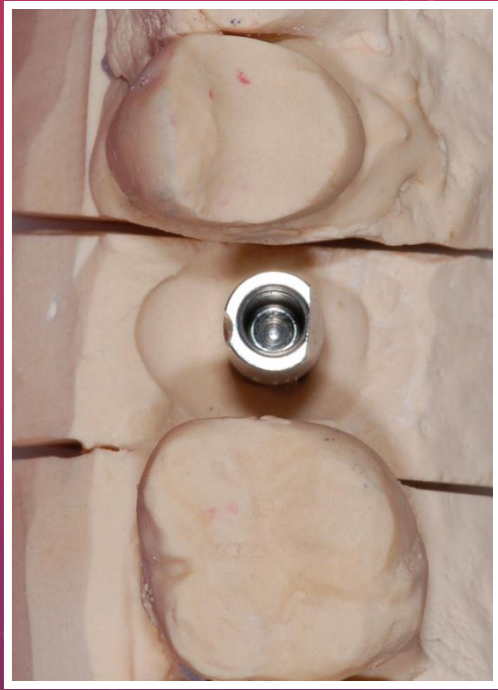


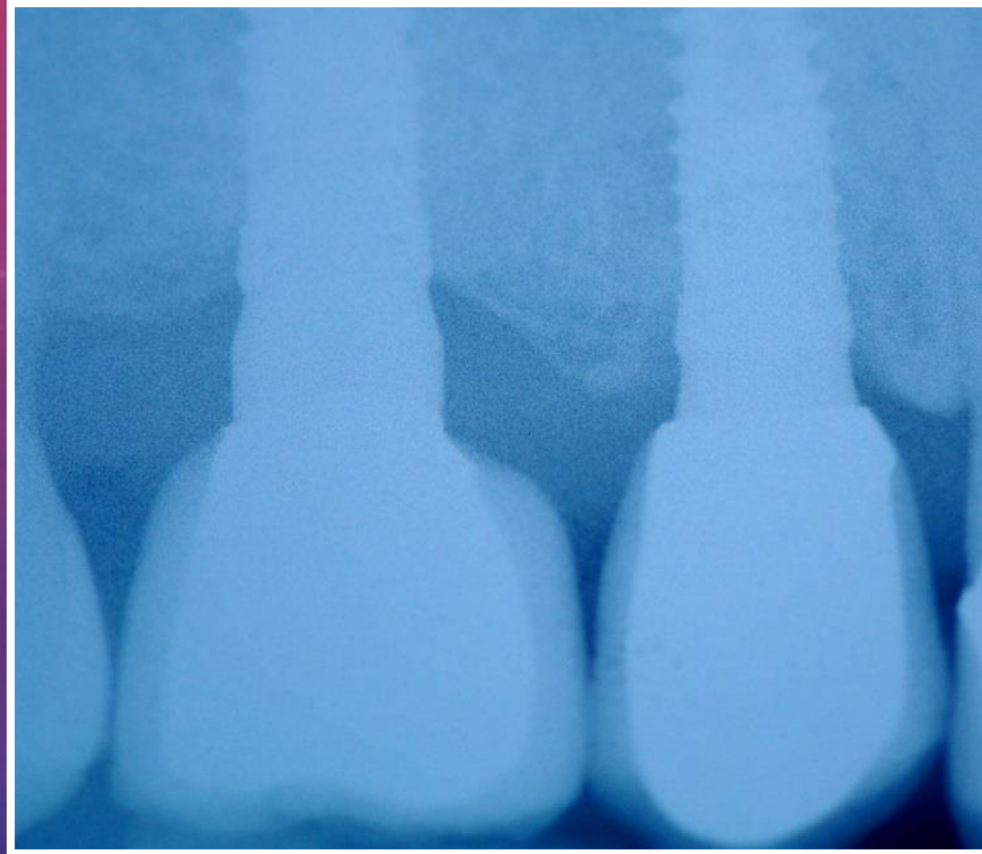
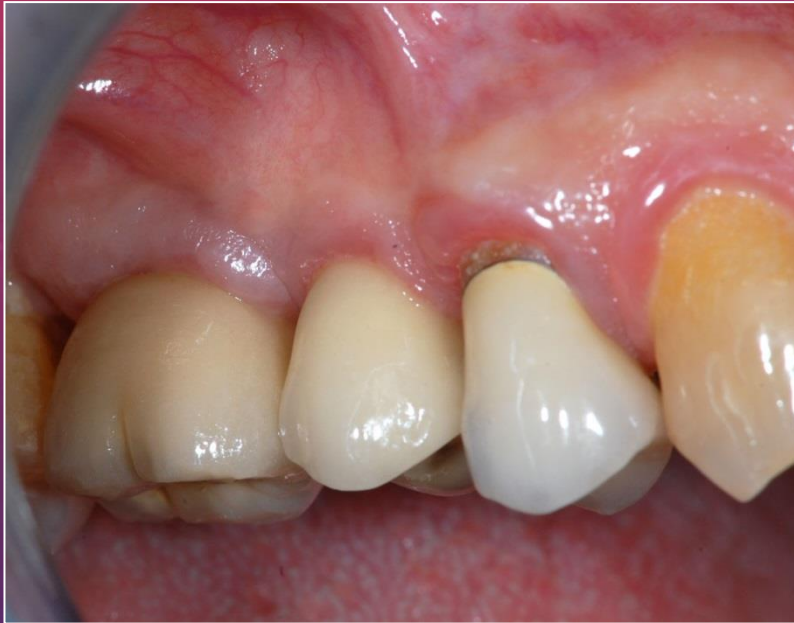Implantation



After 3 months

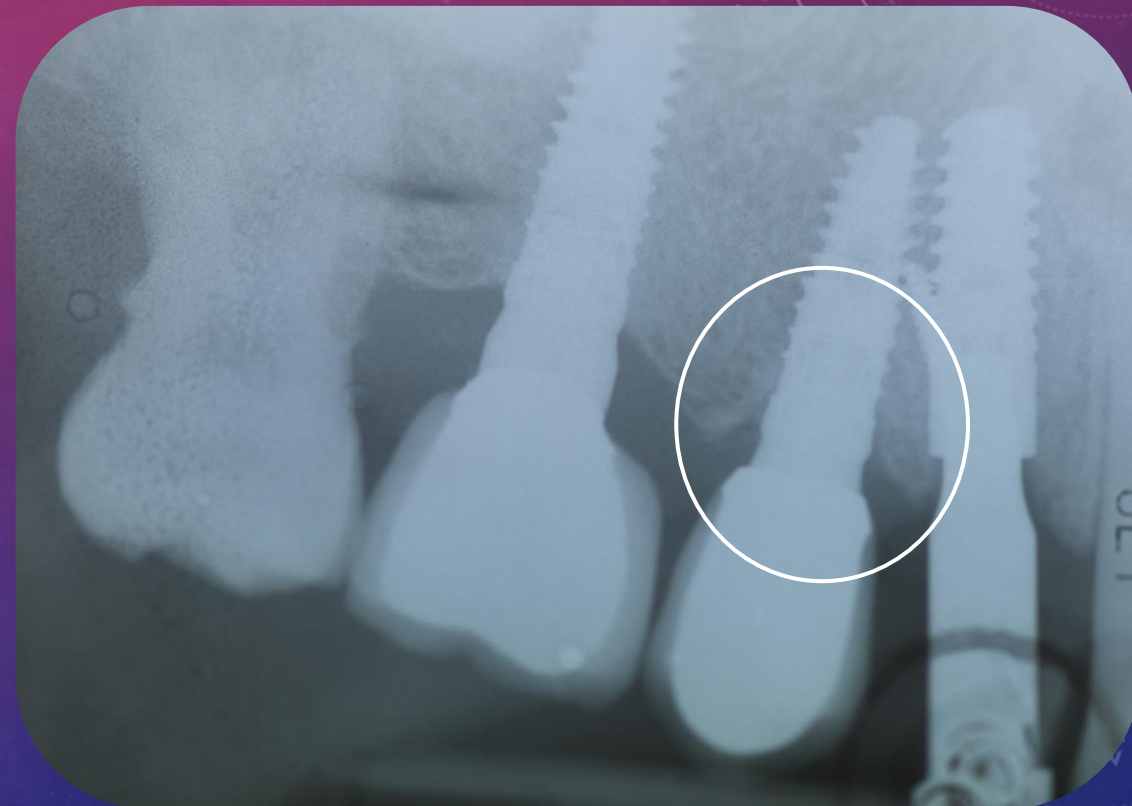
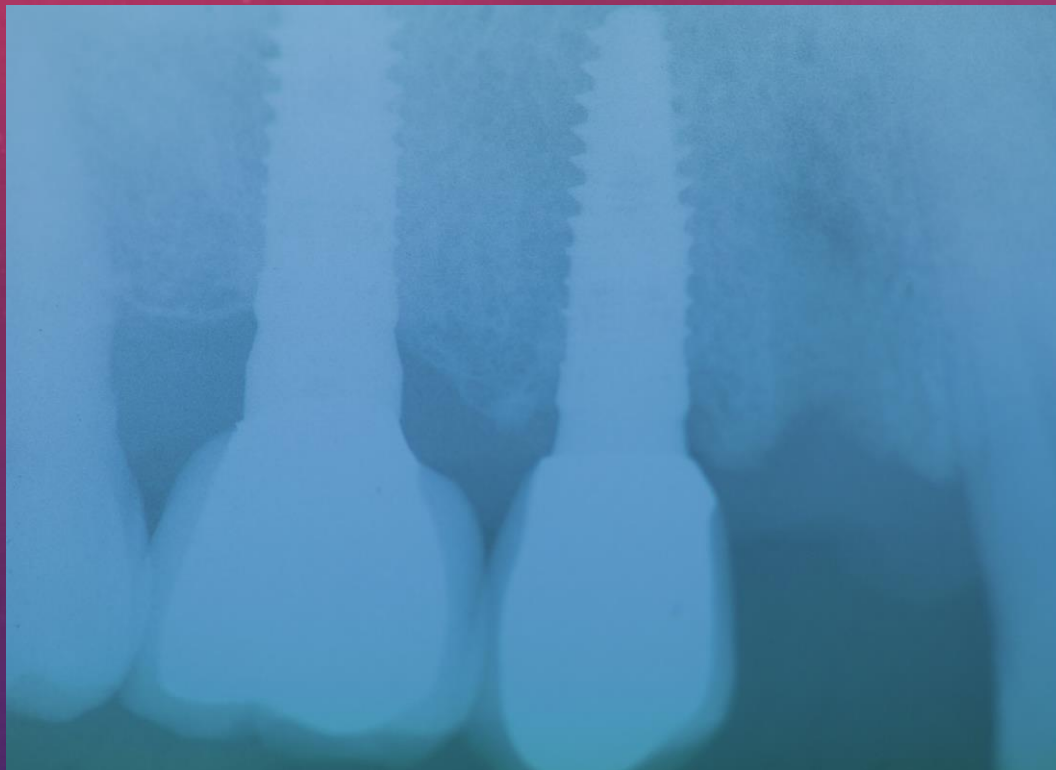


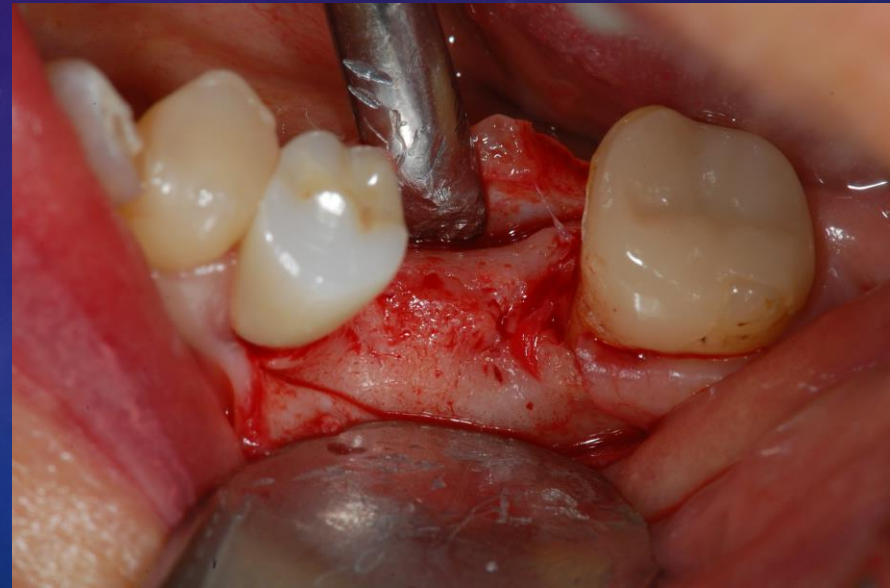
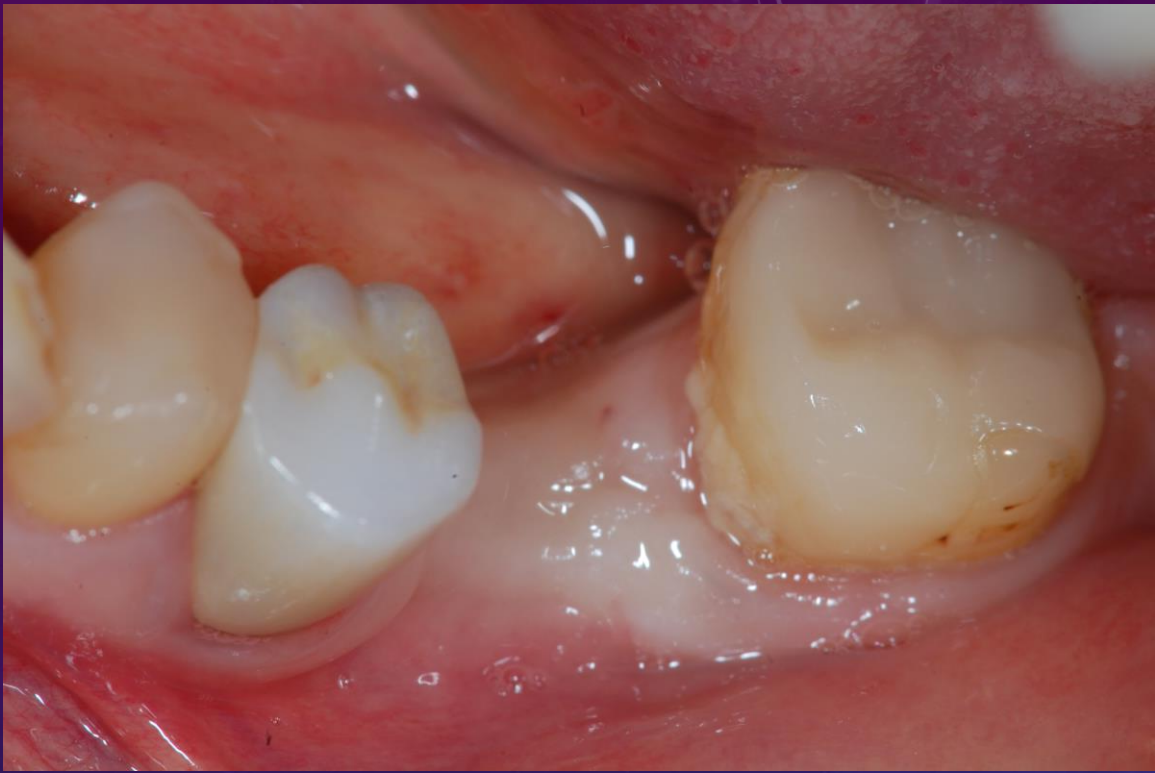

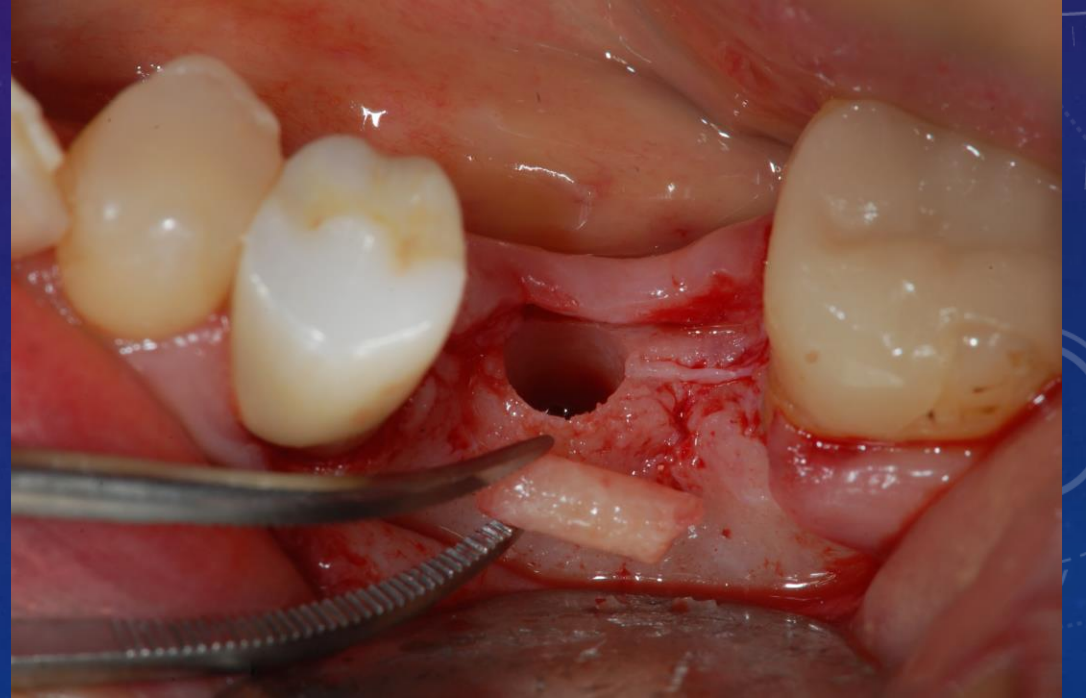
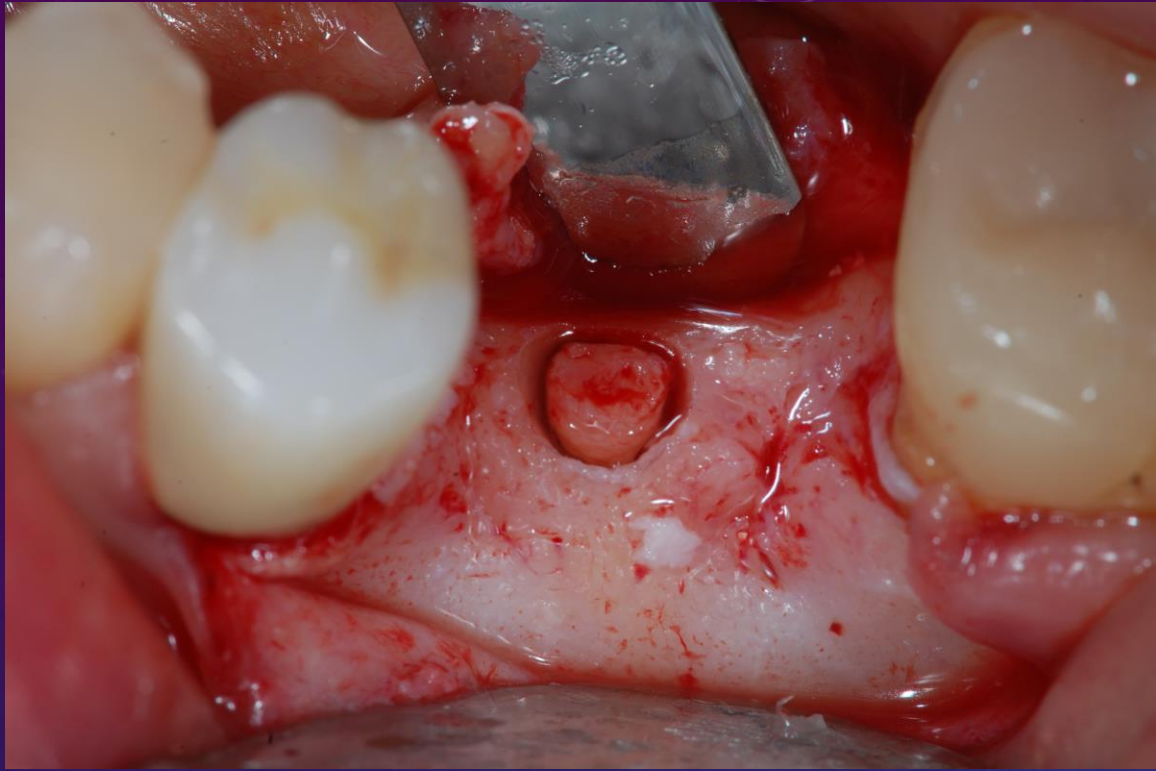


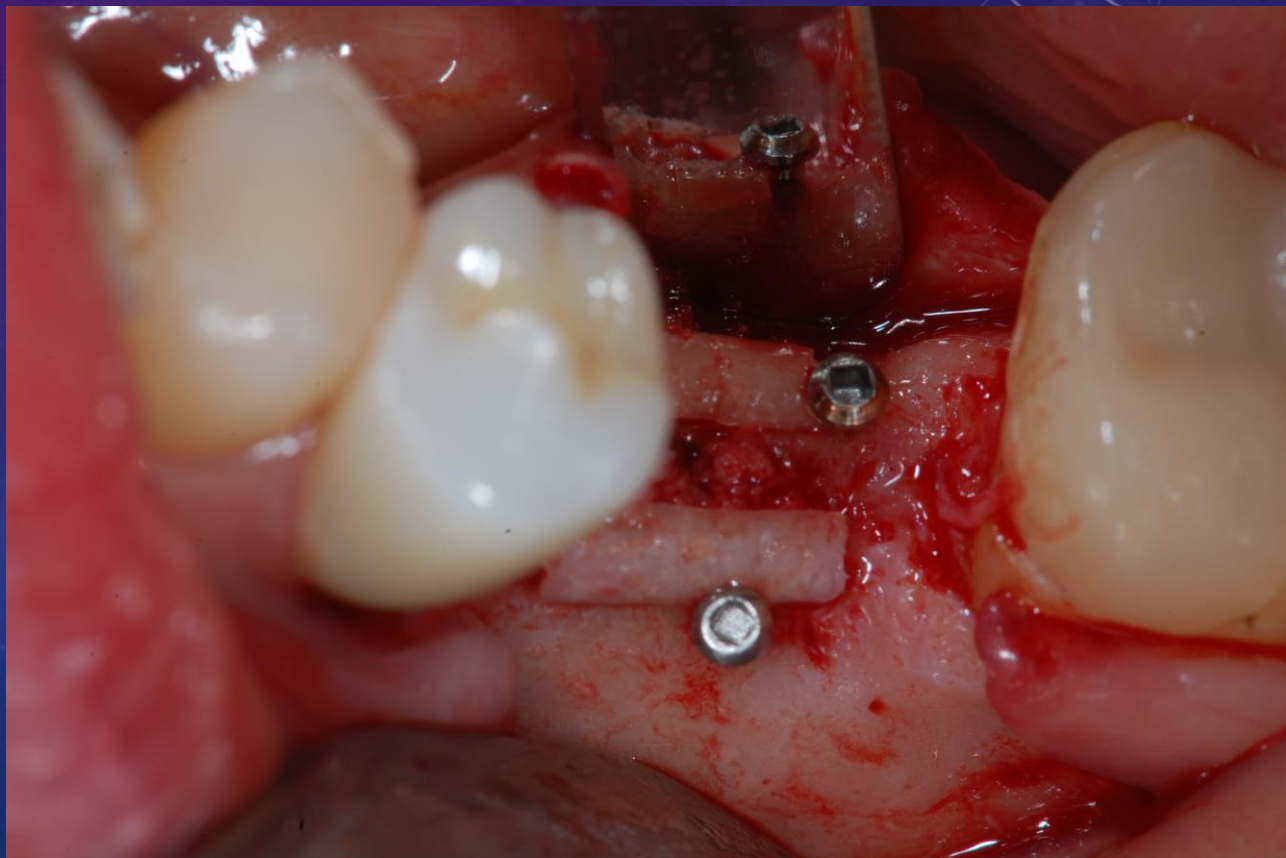
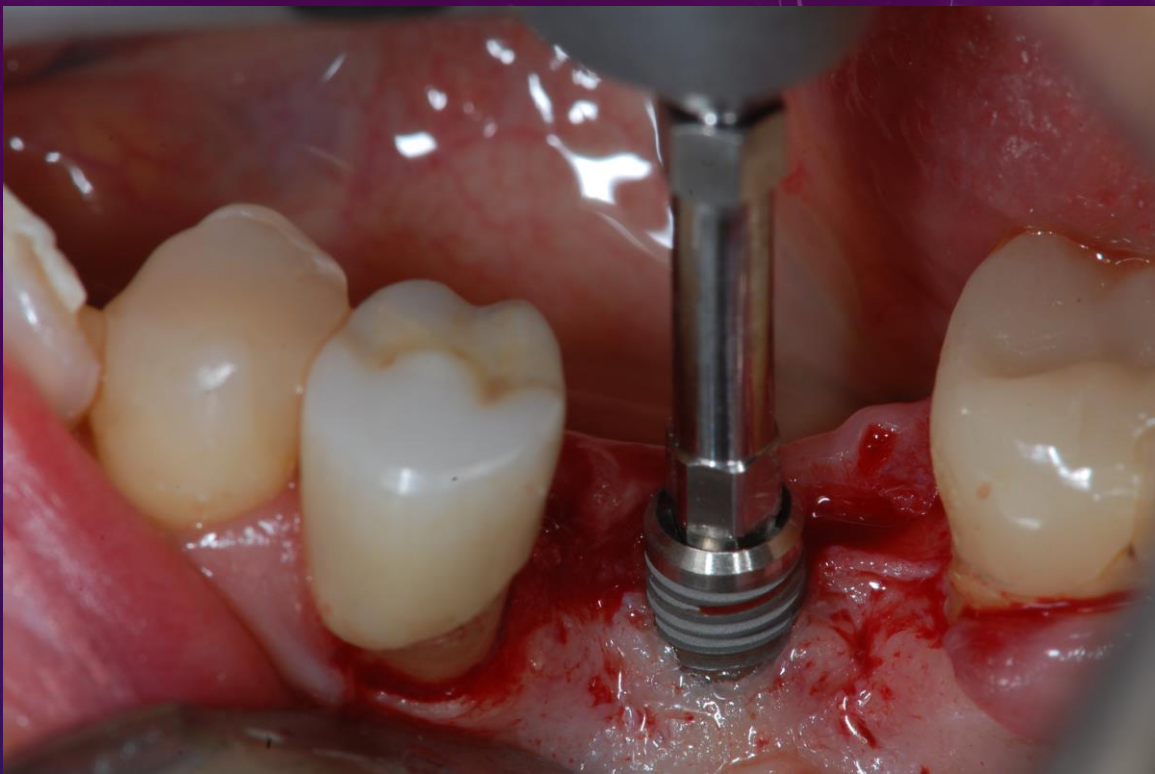
Stable bone level after four years!

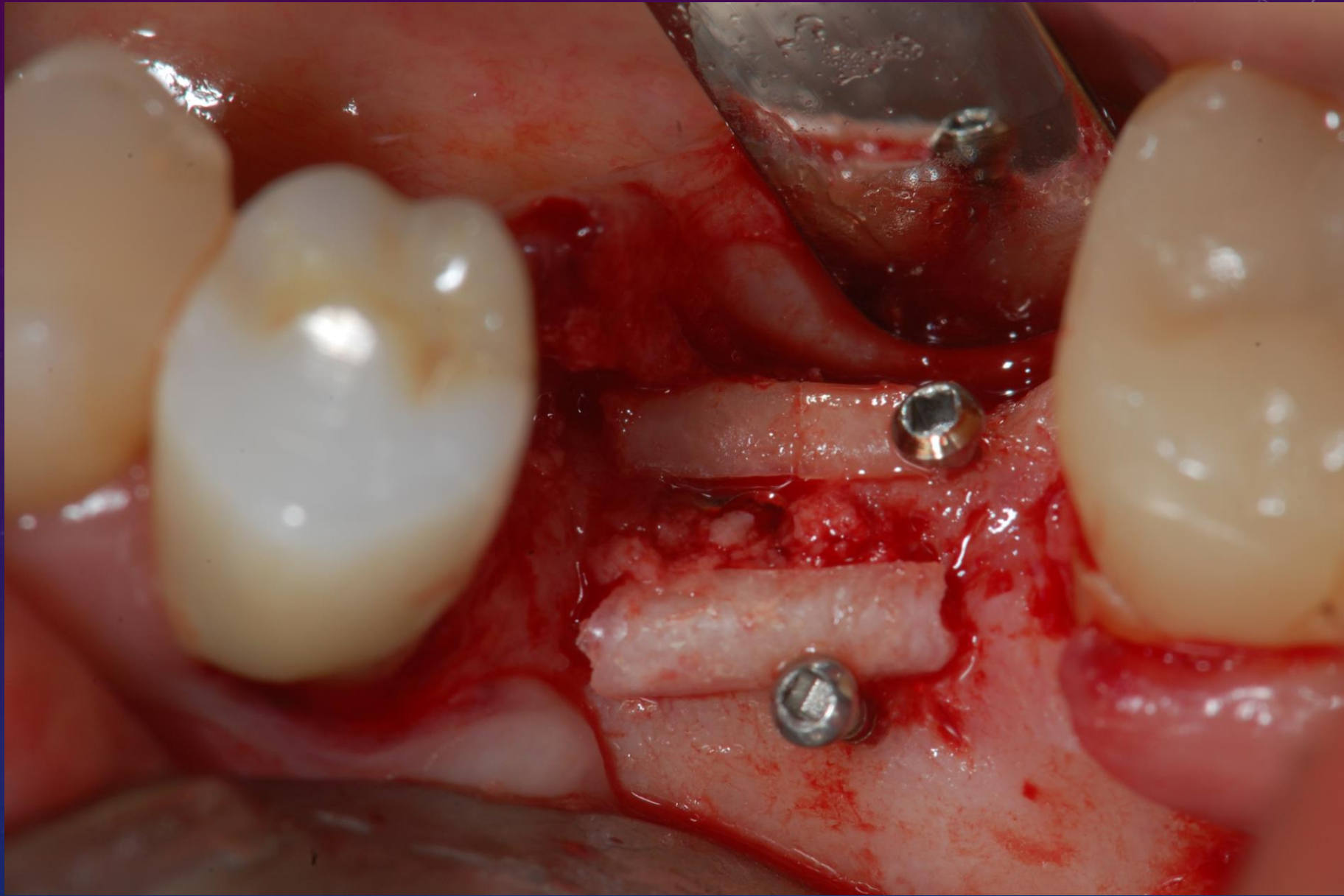
STABLE BONE LEVEL AFTER 8 YEARS

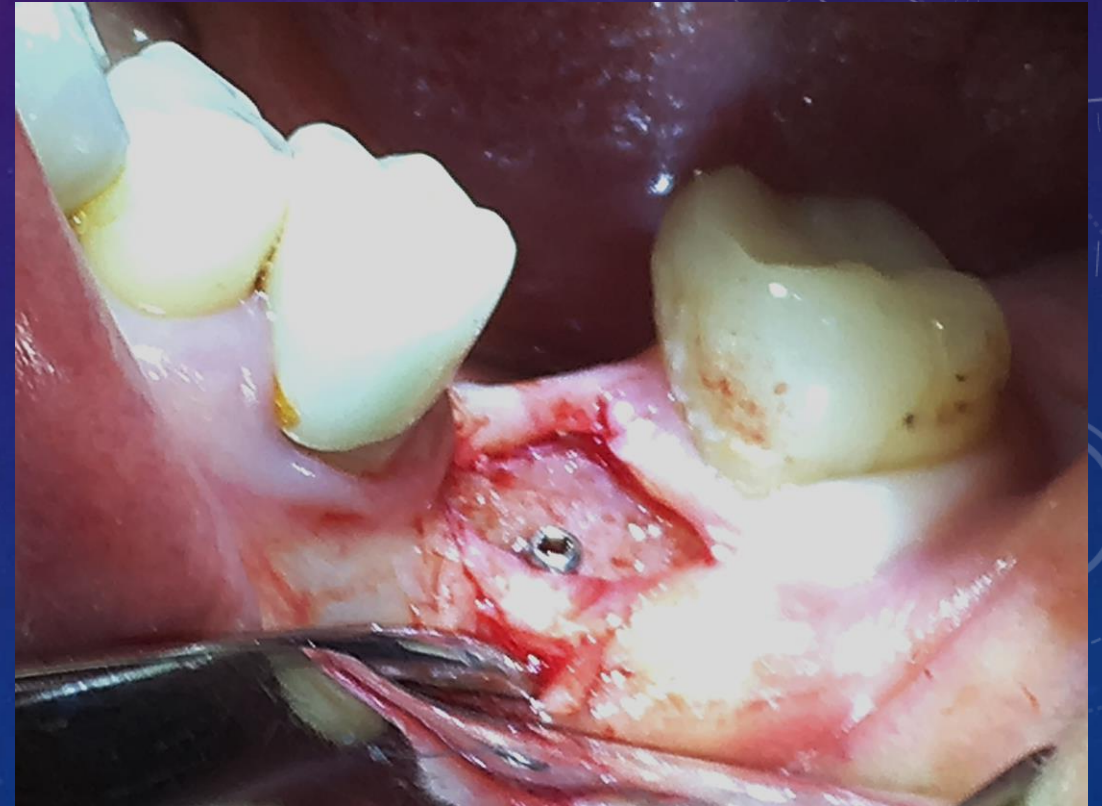
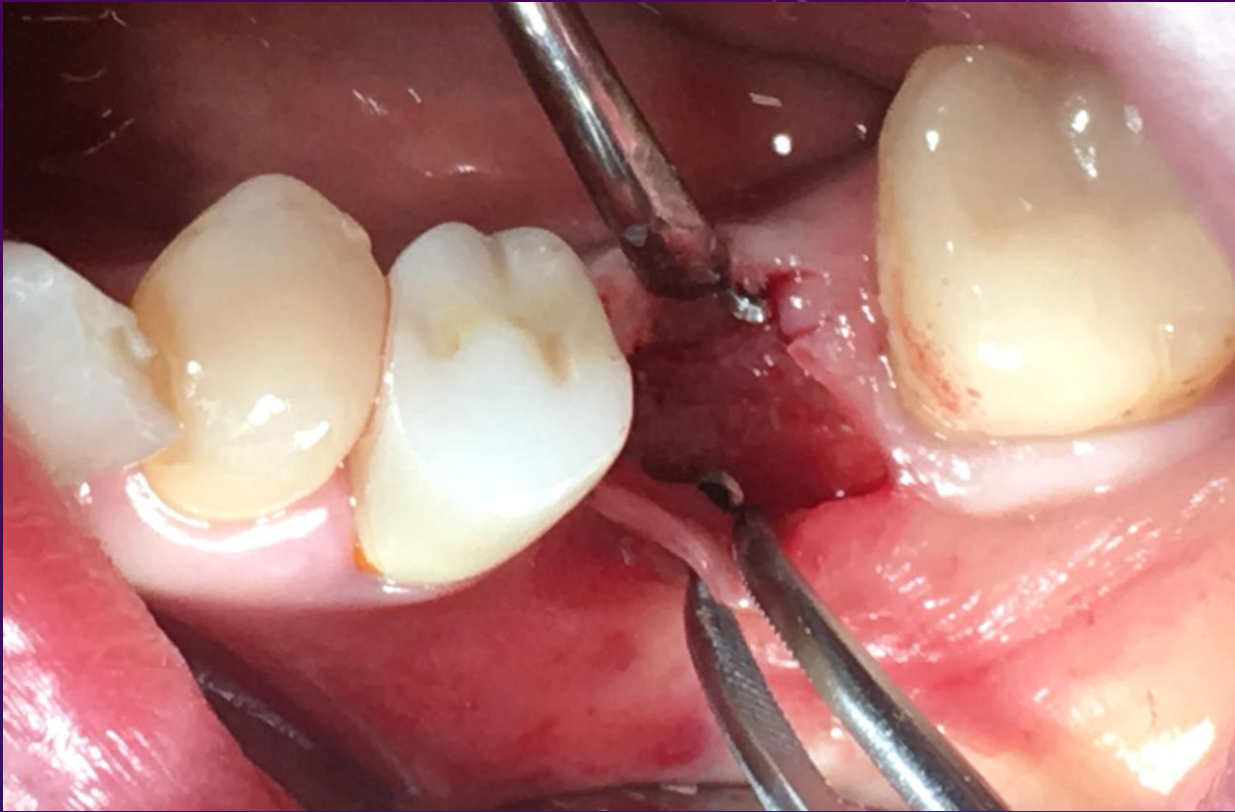


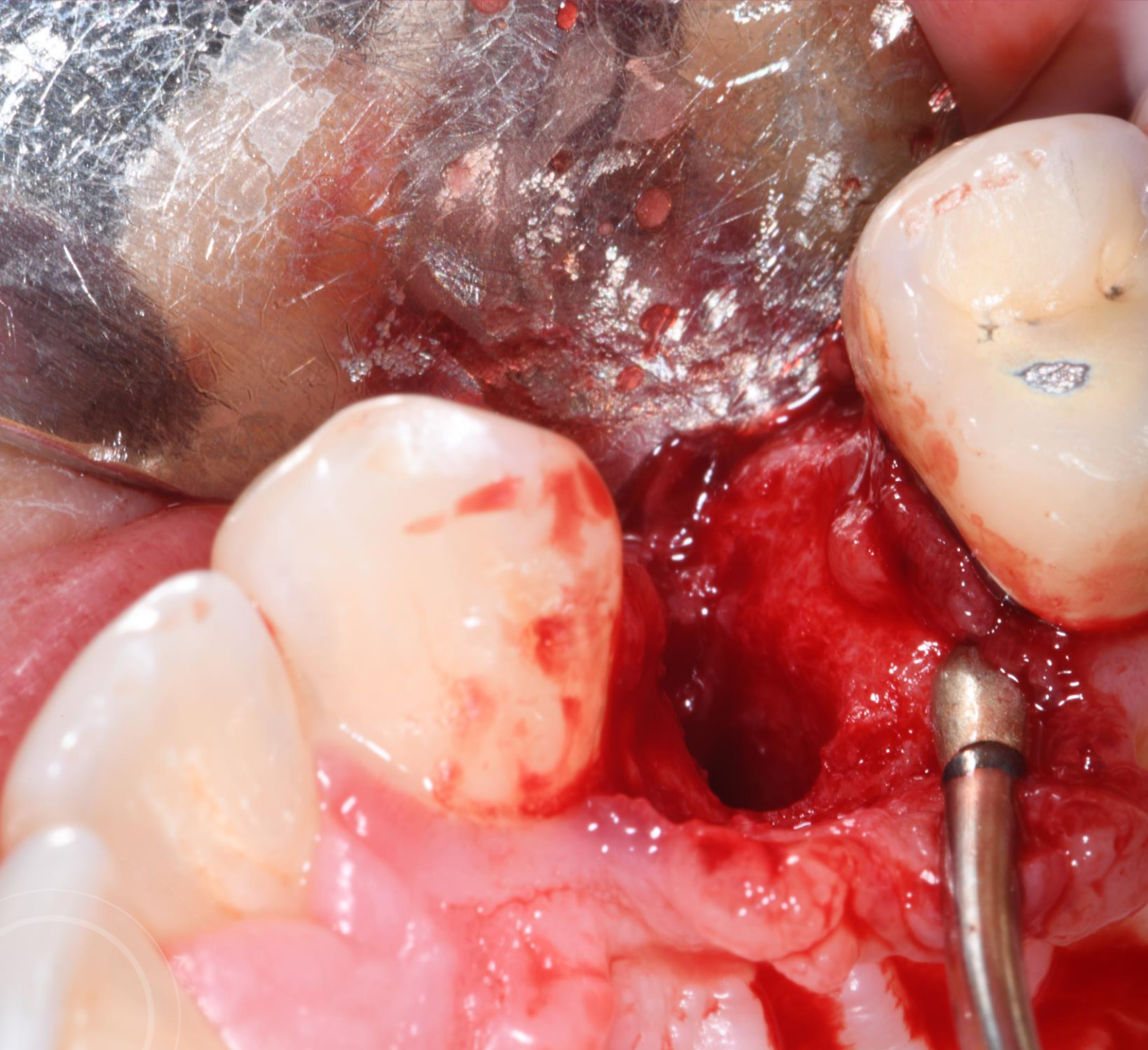




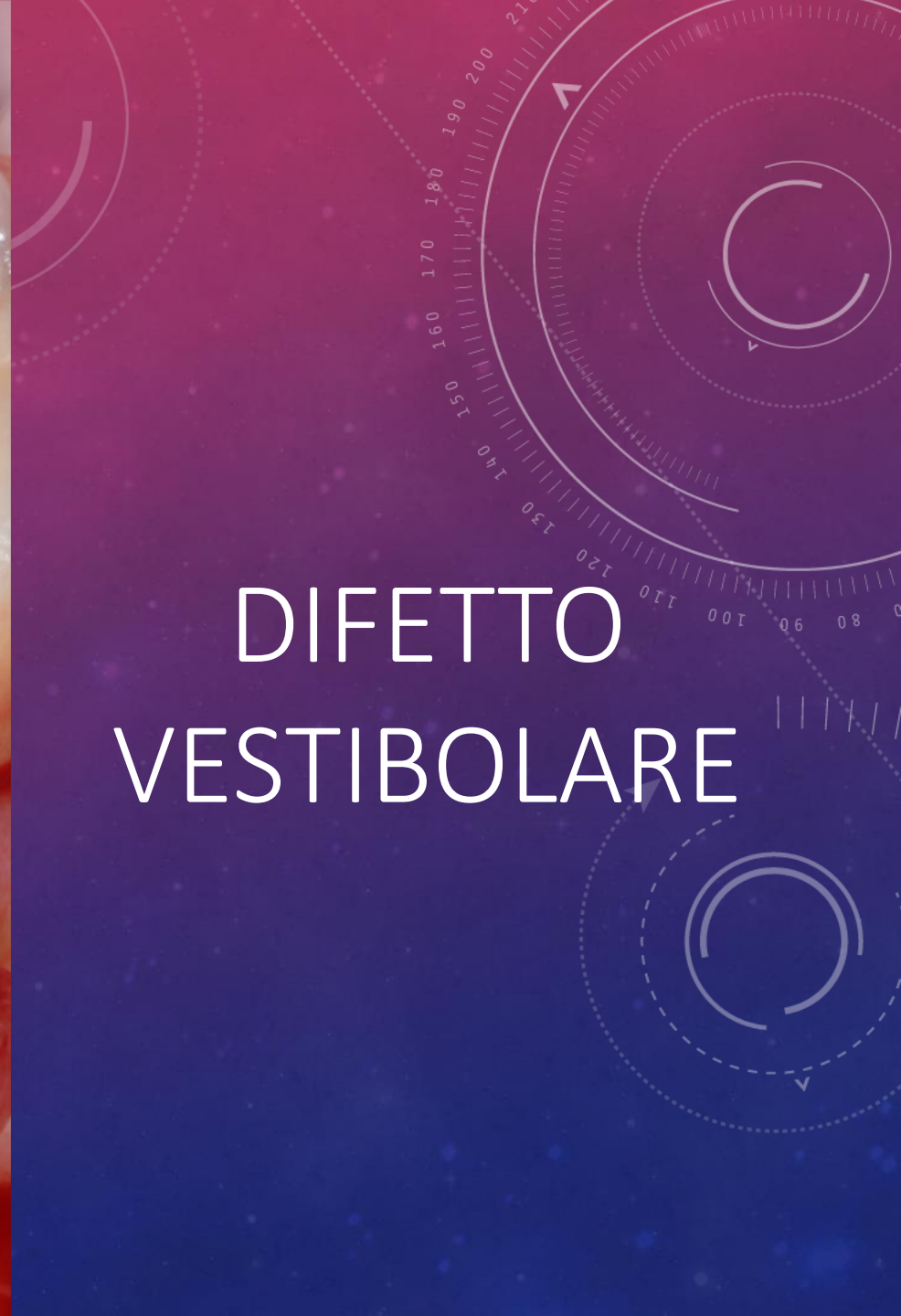


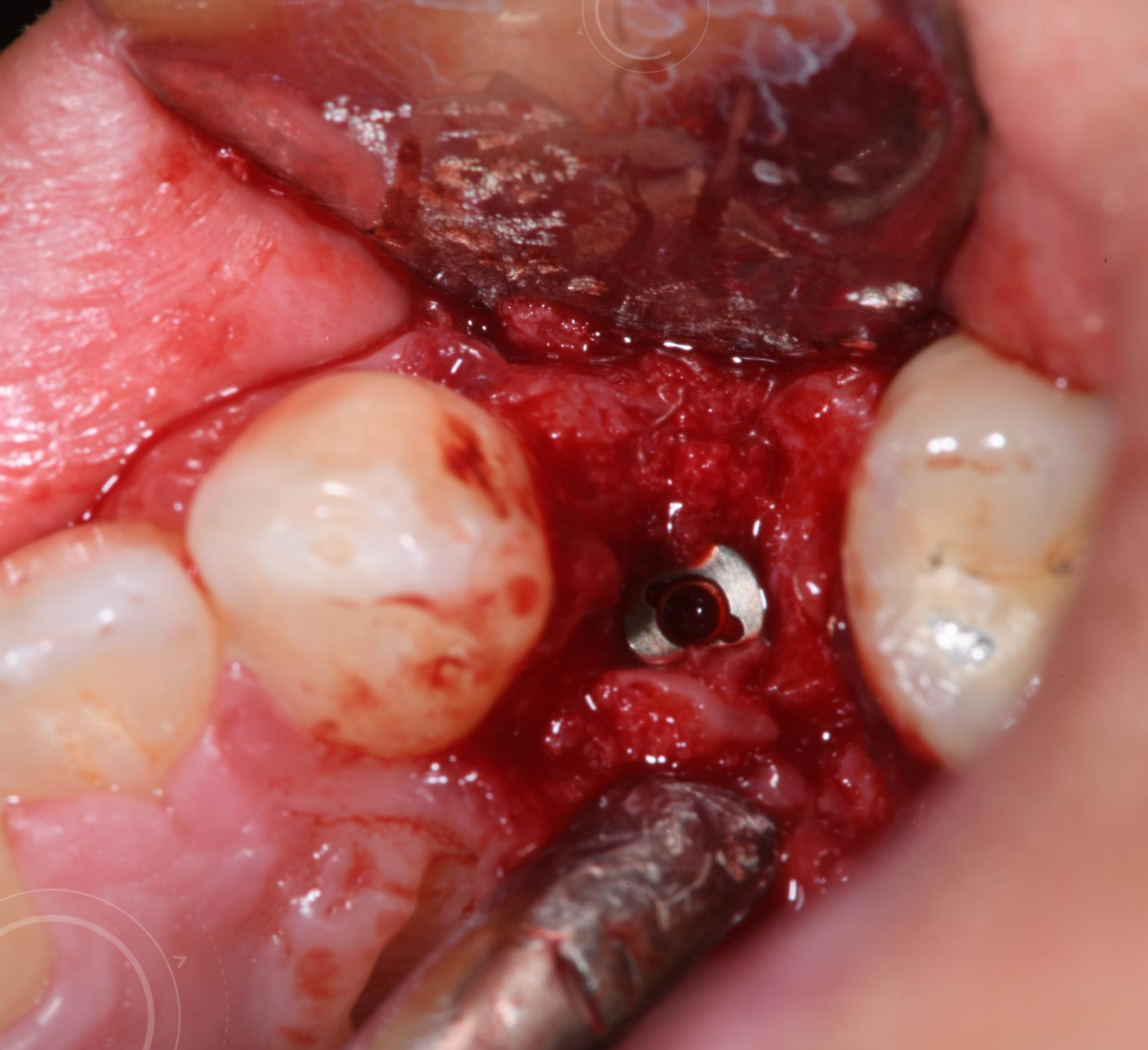

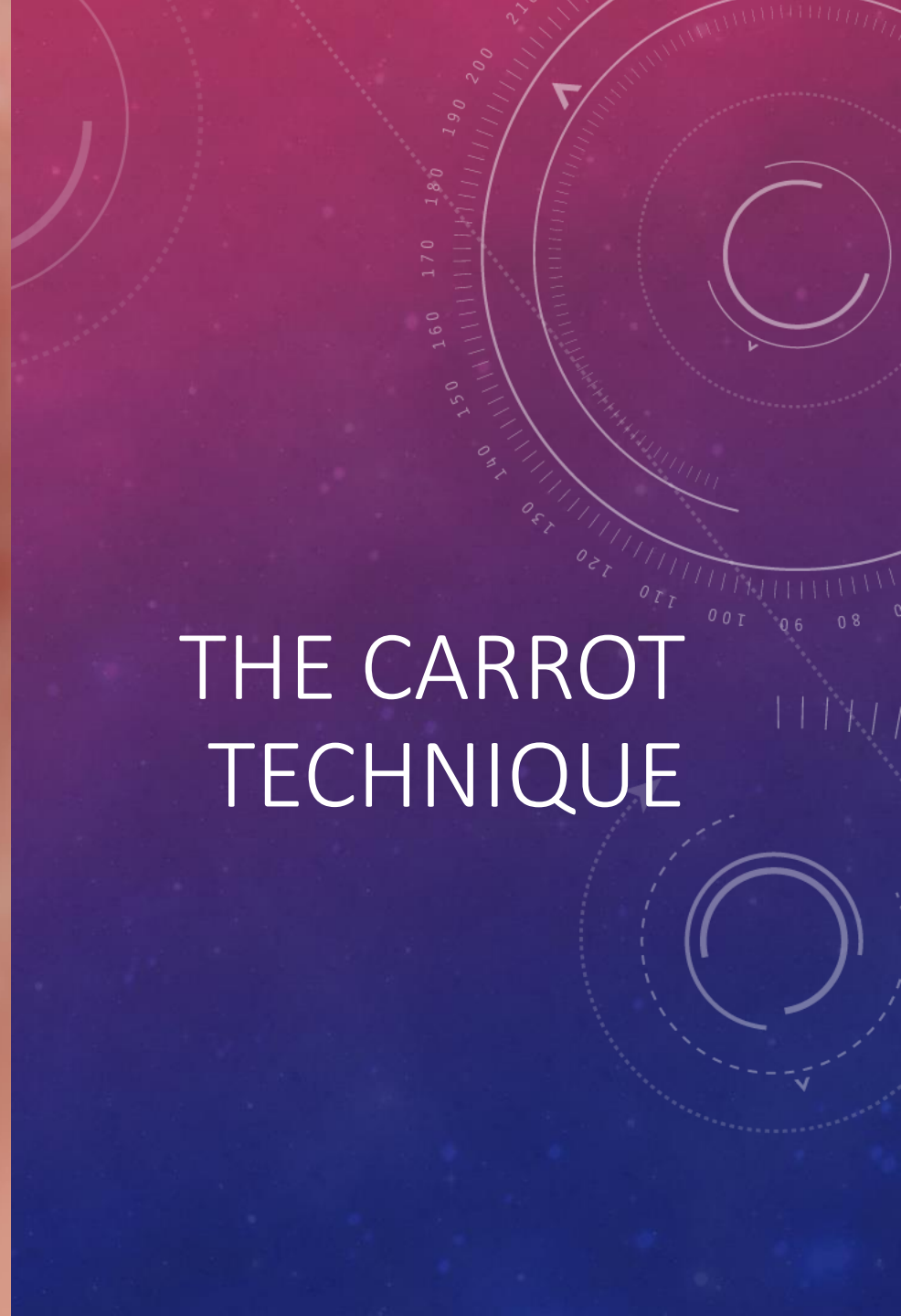


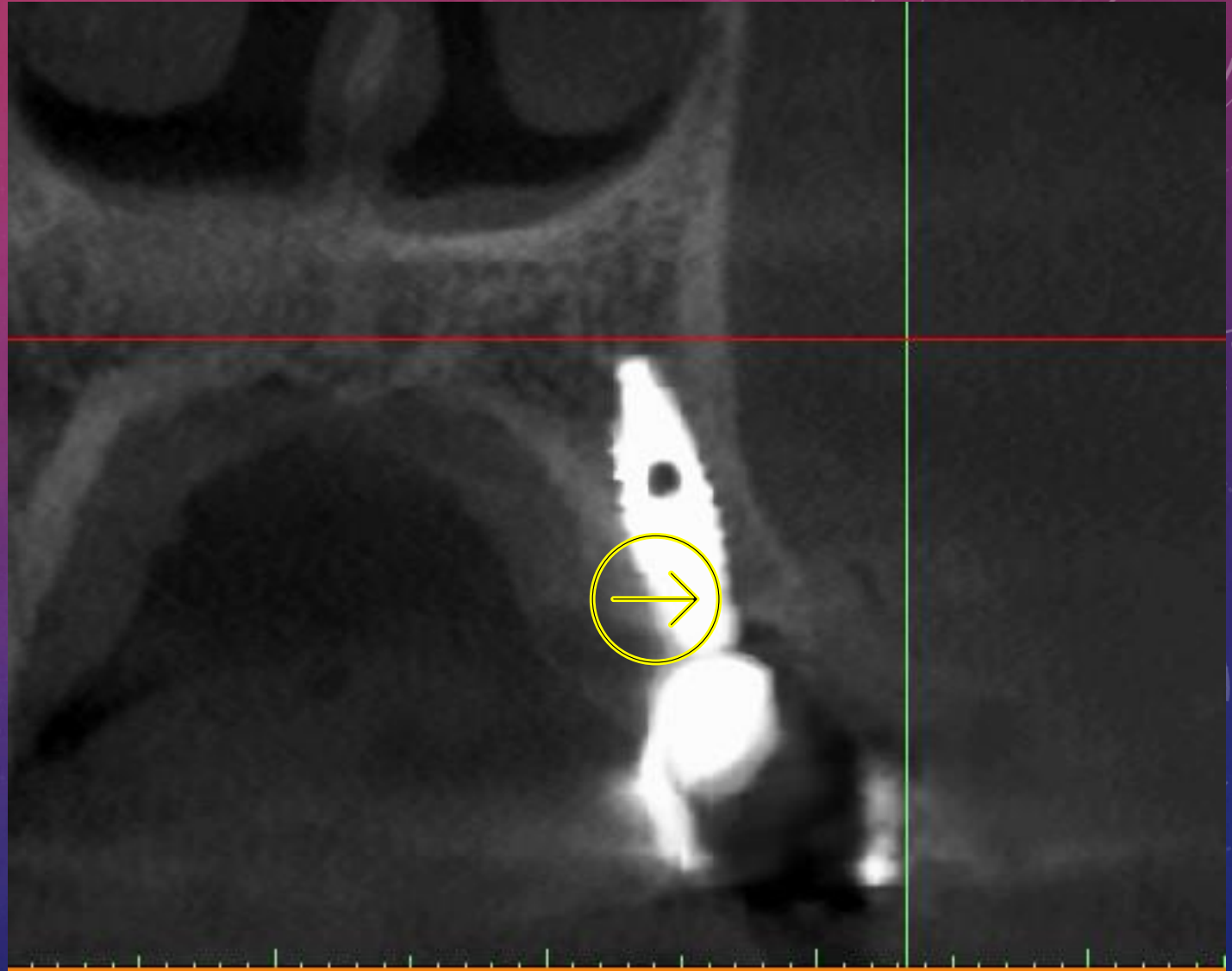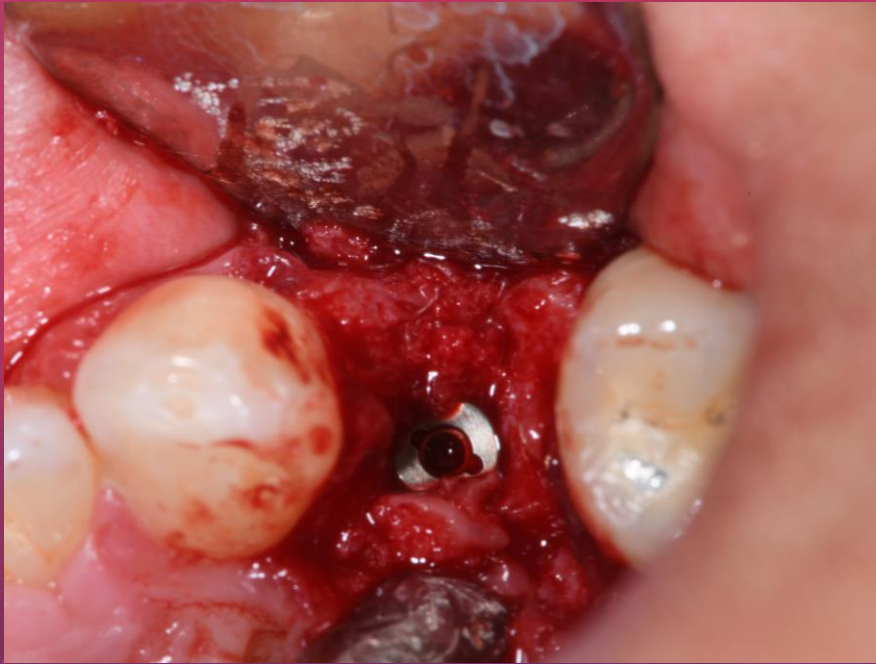
DIFETTO VESTIBOLARE





THE CARROT TECHNIQUE





3 YEARS

