

# SMARTBRANE

Resorbable Pericardium Membrane

THE SMARTER MEMBRANE



# SMARTBRANE

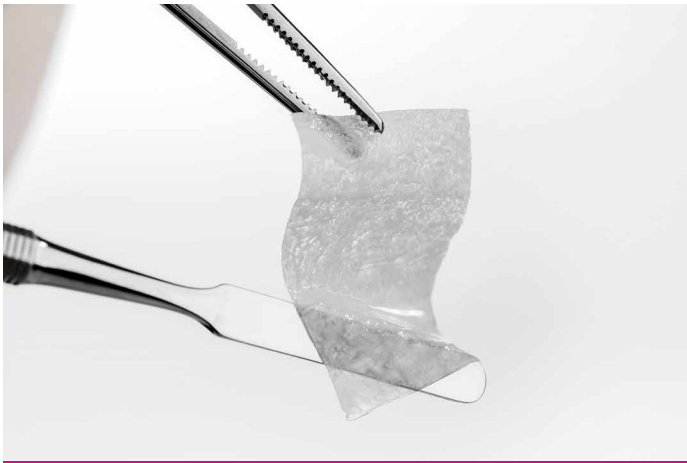
RESORBABLE PERICARDIUM MEMBRANE

- **HANDLING** – Adaptable to bony surface without sticking.
- **BARRIER** – Smartbrane has a resorption time of 8-12 weeks that can even be extended.<sup>7</sup>
- **PURE** – Innovative technology that results in high purity.
- **SIZES** – From mini to large.

## HANDLING

Adaptable to bony surface without sticking.

Simple membrane handling (dry and wet) with high mechanical strength, adequate for use in standard GBR cases. Smartbrane has adequate tensile strength to safely maintain bone graft stability and structure.



*Smartbrane rehydrated: excellent adaptation to surfaces without sticking to graft or instrument.*

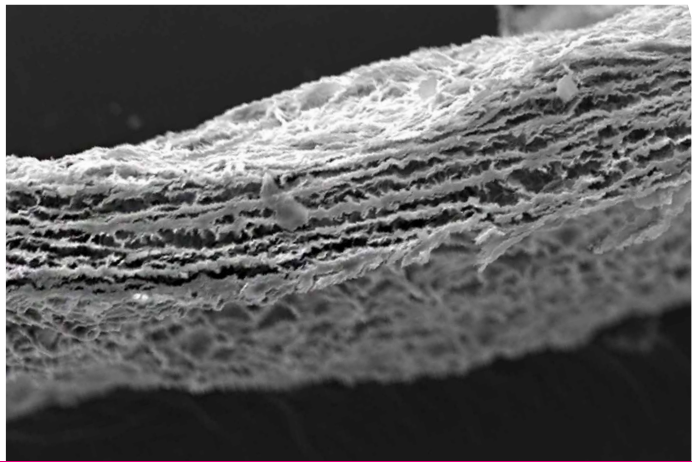



## BARRIER

Smartbrane has a resorption time of 8-12 weeks that can even be extended with the application of Hyadent BG.<sup>6,7,\*</sup>

## SIZES

The appropriate size for different indications:  
Less cutting and less material waste.



\* application of surgical-grade hyaluronic acid together with Smartbrane can significantly reduce the degradation rate in compromised situations (in vivo trial with diabetic and healthy rats).<sup>16</sup>

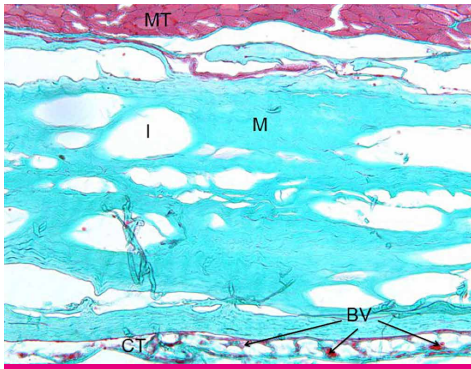
## PURE

Innovative processing technology that results in a biocompatible membrane.

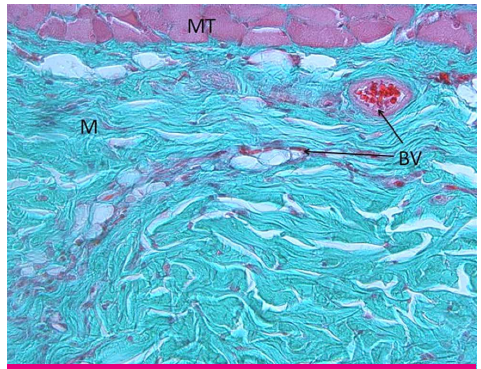
The proprietary cleaning process using supercritical carbon dioxide (scCO<sub>2</sub>) gently removes unwanted materials (e.g cells, lipids) while preserving the natural collagen matrix and the natural cross-linking of the collagen fibers.<sup>1,2</sup>

- Porcine pericardium membrane biocompatibility results in adequate barrier functionality.
- Natural collagen matrix plays an important role in blood clotting and enables cell attachment.<sup>5</sup>

### HISTOLOGICAL EXAMINATION IN VIVO<sup>4</sup>



One week after subcutaneous implantation in a rat muscle: Smartbrane (M) is already connected to the muscular tissue (MT), no signs of inflammatory reactions.



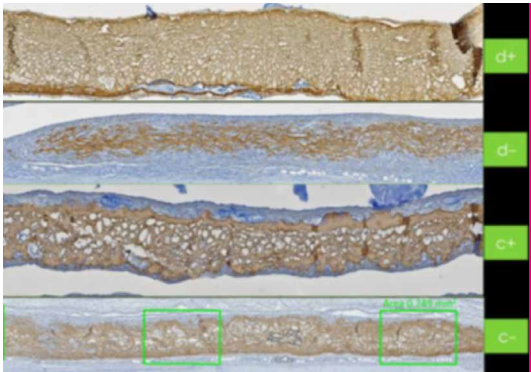
Two weeks after implantation: the first blood vessels (BV) are sprouting into Smartbrane (M), no signs of inflammatory reactions.



# SIX REASONS

TO ADD HYALURONIC ACID TO SMARTBRANE

- 1** As hydrophilic agent, hyaluronic acid (HA) stabilizes blood clot and attracts growth factors to support and accelerate bone formation.<sup>11-14</sup>
- 2** HA supports angiogenesis.<sup>15</sup>
- 3** HA's high molecular weight reduces swelling and discomfort while supporting scar-less healing.<sup>16</sup>
- 4** HA has natural bacteriostatic properties.<sup>17</sup>
- 5** HA's special formulation remains present throughout the various phases of the healing process due to its slow degradation pattern (several weeks).<sup>13</sup>
- 6** Smartbrane has a resorption time of 8-12 weeks that can even be extended with Hyadent BG.<sup>6,7,\*</sup>



Collagen membranes (brown), 14 days after implantation in normoglycemic (C-/C1) or diabetic groups (d-/d+) show less collagen resorption when used with Hyadent BG (d+/c+).<sup>6,7</sup>



# AVAILABLE PRODUCTS

## SMARTBRANE

Size	Article number
10 x 10 mm	0121.200
15 x 20 mm	0121.201
20 x 30 mm	0121.202
30 x 40 mm	0121.203



## SMARTGRAFT

Size	Article number
0.50 cc / 0.25 – 1.00 mm	0114.101
1.00 cc / 0.25 – 1.00 mm	0114.102
2.00 cc / 0.25 – 1.00 mm	0114.103
4.00 cc / 0.25 – 1.00 mm	0114.105
1.00 cc / 1.00 – 2.00 mm	0114.112
2.00 cc / 1.00 – 2.00 mm	0114.113
0.25 cc / 0.25 – 1.00 mm syringe	0114.450
0.50 cc / 0.25 – 1.00 mm syringe	0114.451



## hyadENT BG

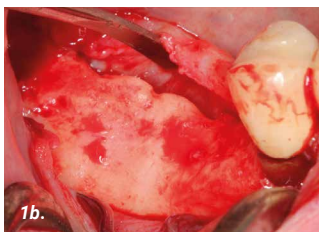
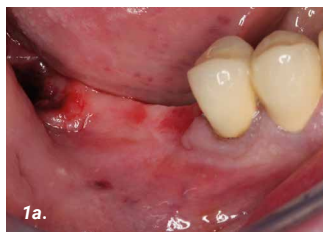Size	Article number
2 x 1.2 ml ampulla	BS091



Note: Smartbrane is a registered brand and manufactured by Regedent AG.  
Smartgraft is a registered brand of Regedent AG and manufactured by Collagen Matrix Inc. Hyadent BG is a registered brand and manufactured by BioScience GmbH.

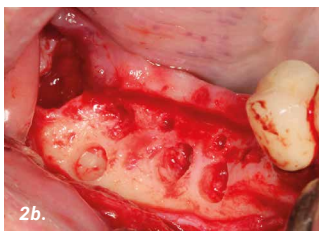
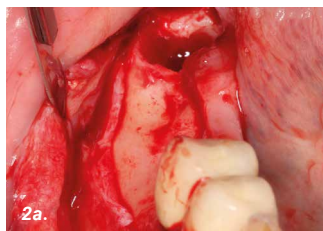
# GBR PRIOR TO IMPLANT PLACEMENT

CASE PROVIDED BY PROF DARKO BOŽIĆ, ZAGREB, CROATIA



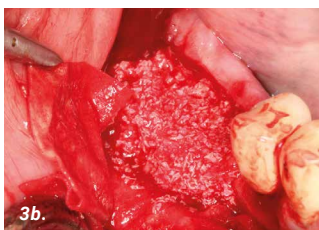
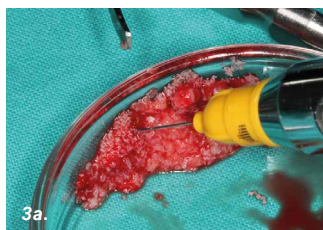
1a. Patient with a distal mandibular edentulous ridge requiring implant placement.

1b. Flap elevation revealed significant loss of ridge height and width.



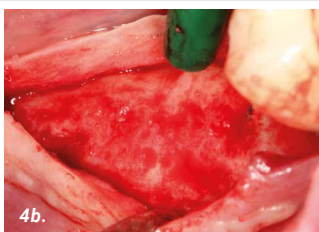
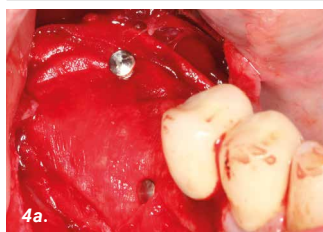2a. Edentulous ridge with significant loss of height and width.

2b. A small amount of autogenous bone was harvested leaving small cortical perforations.



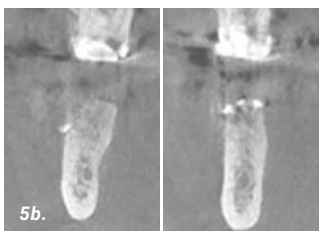
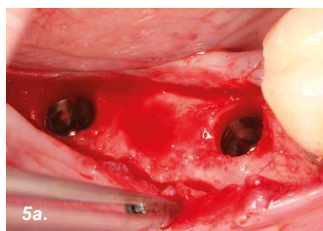
3a. The autogenous bone was mixed with xenograft material saturated with hyaluronic acid.

3b. Placement and adaptation of the graft mixture onto the recipient site.



4a. The graft mixture was covered with a resorbable collagen membrane (Smartbrane) and fixed with pins.

4b. AFTER 6 MONTHS  
Significant gain of bone width with almost no residual graft particles visible.

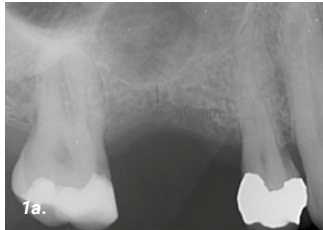

5a. Implants of 4mm width were placed in the correct prosthetic positions.

5b. AFTER 6 MONTHS  
Cone beam computed tomography (CBCT) showing a significant amount of newly formed bone.

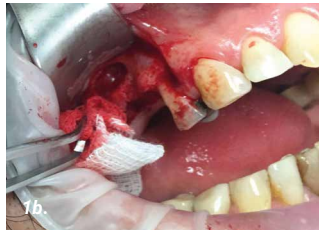
# SINUS ELEVATION

CASE PROVIDED BY DR H. JAMBREC, GENEVA, SWITZERLAND



## 1a. PRE-OPERATIVE

X-ray showing a bone height of 4 mm, which is not enough to place an implant.

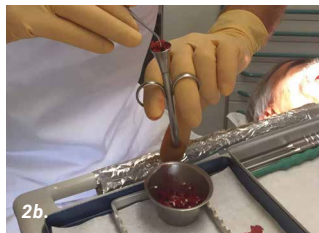

## 1b. SURGERY

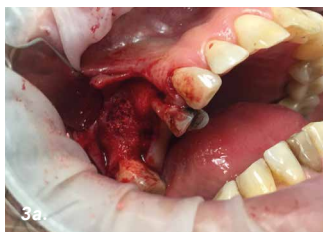After preparing the flap, a small fenestration (size ~8 mm) was made to access the sinus.



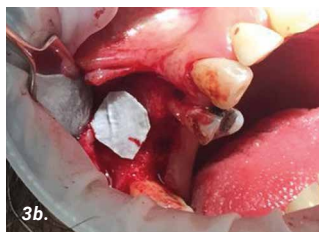2a. Mixing of xenograft (granules 1-2 mm / 3.6 cc) with blood.



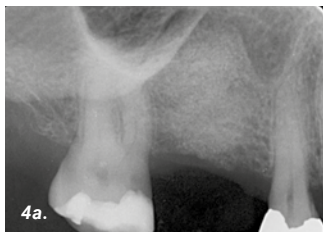
2b. Filling of tube with xenograft.



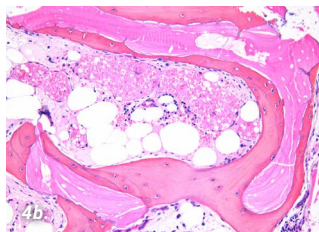
3a. Filling of sinus cavity.



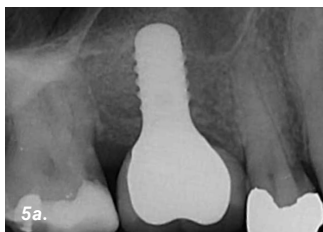
3b. Fenestration covered with very small pericardium membrane (Smartbrane size: 10 x 10 mm).



4a. 6 MONTH POST-OPERATIVE  
Bone height of around 14 mm was achieved.



4b. HISTOLOGICAL PICTURE  
Image showing vital bone completely surrounding the graft material.

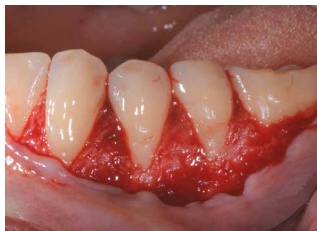
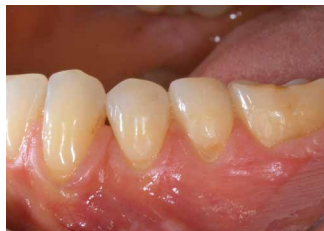
5a. 20 MONTH POST-OPERATIVE  
Situation 20 months after grafting procedure. Implant seems well integrated and bone height looks stable.



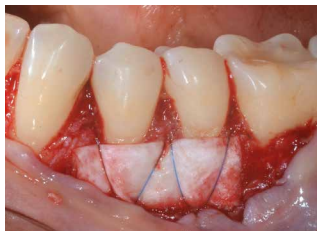# MULTIPLE RECESSION COVERAGE

CASE PROVIDED BY DR THOMAS PIERCHALLA, MUNSTER, GERMANY



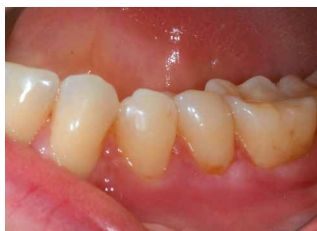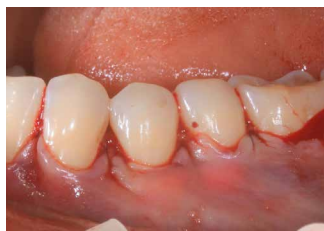**1a.** PRE-OPERATIVE  
Baseline

**1b.** SURGERY  
Open flap (CAF protocol)



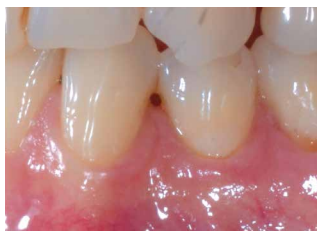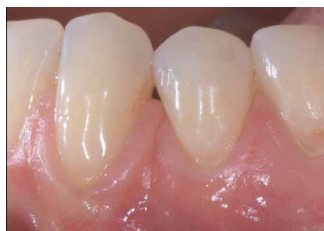**2a.** Smartbrane coated with  
Hyadent BG and folded.

**2b.** Suturing on tooth surface of the  
folded Smartbrane coated with  
Hyadent BG.



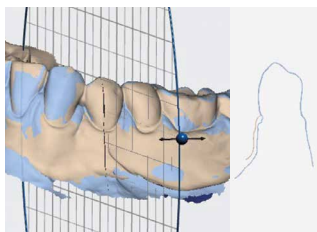
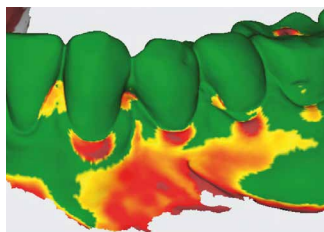
**3a.** Suturing the flap.

**3b.** 14 DAYS POST-OPERATIVE



**4a.** POST-OPERATIVE

**4b.** 9 MONTH POST-OPERATIVE



**5a.** Soft-tissue volume gain at  
9 months post-op vs baseline.

**5b.** Cross-section at 9 months  
post-op vs baseline.

# OPTIONS PER INDICATIONS

INDICATIONS	SMARTGRAFT	SMARTBRANE	HYADENT BG
Root coverage with CTG			1 x 1.2 ml
Intraosseous defect (1-3 walls) Furcation	0.25 – 1.0 mm granules	15 x 20 mm	1 x 1.2 ml
Fenestration defect	0.5 cc or 1 cc of fine particles	20 x 30 mm	1 x 1.2 ml
Implant dehiscence	0.5 cc or 1 cc of fine particles	15 x 20 mm	1 x 1,2 ml
Extraction socket	1.0 cc of fine particles	10 x 10 mm or 15 x 20 mm	1 x 1.2 ml
Vertical / horizontal augmentation	2.0 cc of large particles	20 x 30 mm or 30 x 40mm	1 x 1.2 ml
Ridge preservation	2.0 cc of large particles	30 x 40mm	1 x 1.2 ml
Sinus floor elevation	2.0 cc of large particles	15 x 20mm / 20 x 30 mm	1 x 1.2 ml
Protection Schneiderian membrane		15 x 20 mm or 20 x 30 mm	1 x 1.2 ml

## LITERATURE

- Nichols A, Burns DC, Christopher R. Studies on the Sterilization of Human Bone and Tendon Musculoskeletal Allograft Tissue Using Supercritical Carbon Dioxide. *Journal of Orthopaedics* 2009.
- Sawada K, Terada D, Yamaoka T, Kitamura S, Fujisato T. Cell removal with supercritical carbon dioxide for acellular artificial tissue. *J Chemical Technol Biotechnol* 2008;83(6):943–949.
- Internal testing results, data on file.
- SMARTBRANE subcutaneous implantation test, data on file.
- Brett D. A Review of Collagen and Collagen-based Wound Dressings. *Wounds* 2008;20(12).
- Internal testing results, data on file.
- Eliezer M, Sculean A, Miron RJ, et al. 'Hyaluronic acid slows down collagen membrane degradation in uncontrolled diabetic rats.' *J Periodontal Res.* 2019;00:1–9.
- Deligianni DD, Katsala ND, Koutsoukos PG, Missirlis YF, Effect of Surface Roughness of Hydroxyapatite on Human Bone Marrow Cell Adhesion, Proliferation, Differentiation and Detachment Strength. *Elsevier iomaterials* 22 (2001) 87–96
- Frank M, Klenke, Yuelian Liu, Huijin Yuan, Ernst B. Hunziker, Klaus A. Siebenrock, Willy Hofstetter. Impact of Pore Size on the Vascularization and Osseointegration of Ceramic Bone Substitutes in vivo. *Journal of Biomedical Materials Research Part A*, 2007, 777-786
- Brett D. A Review of Collagen and Collagen-based Wound Dressings. *Wounds* 2008;20(12).
- Muzaffer A et al. 'The Effect of Hyaluronic Acid-supplemented Bone Graft in Bone Healing: Experimental Study in Rabbits.' *J Biomater Appl* 2006 20:209
- Sasaki T, Watanabe C. 'Stimulation of osteoinduction in bone wound healing by high-molecular hyaluronic acid.' *Bone*. Vol. 16.No.1 January 1995:9-15
- Stiller M et al. 'Performance of  $\beta$ -tricalcium phosphate granules and putty, bone grafting materials after bilateral sinus floor augmentation in humans.' *Biomaterials* 2014;35(10):3154-3163.
- Mendes RM et al. 'Sodium hyaluronate accelerates the healing process in tooth sockets of rat.' *Arch Oral Biol* 2008; 53:1155–1162
- King, S.R., Hickerson, W.L. and Proctor, K.G. (1991) Beneficial Actions of Exogenous Hyaluronic Acid on Wound Healing. *Surgery*, 109, 76-86.
- Asparuhova M, Kiryak D, Eliezer M, Mihov D, Sculean A. 'Activity of two hyaluronan preparations on primary human oral fibroblasts.' *J Periodontal Res* 2018 Sep 27. Epub 2018 Sep 27
- Pirnazar P et al. 'Bacteriostatic effects of hyaluronic acid.' *Journal of Periodontology* 1999;70:370-374